

THE ANATOMY OF

MAXILLARY ANTERIOR TEETH



DENTISCOPE



COLOR CODING

Cusp

Ridge

Fossa

Groove

Pit

Root



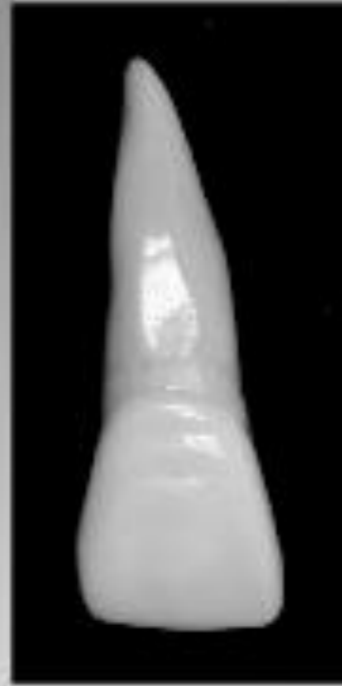MAXILLARY ANTERIOR

	Central Incisors	Lateral Incisors	Canines
Contact Areas	I 3 rd / J M & I 3 rd	J M & I 3 rd / M 3 rd	J M & I 3 rd / M 3 rd
Cingulum	- Distally inclined	-Centered / More prominent than CI	- Centered / Large
Pulp Chamber: L/BL & MD Sections	-Wide @ cervical, tapers to apex	-Distal/mesial/palatal curvature	-Narrow, WIDEST of any anterior tooth @ cervical
Pulp Chamber: Cervical Cross Section	-Pulp Chamber: Cervical Cross Section	-Oval	-Centered, elliptical
Buccal	-Smooth and convex surface -90 degree mesial incisal angle	-Smooth surface -Rounded incisal angles/ Distal is more rounded	-Shallow depressions M/D of LR, concavity found D to LR @ C 3 rd -Labial Ridge -Mesial Incisal Slope is shorter than Distal
Palatal	-Palatal Fossa -Mesial and Distal Marginal Ridges -Incisal Ridge	-Palatal Fossa -Mesial and Distal Marginal Ridges -Incisal Ridge -Common Variation: Lingual Pit / Peg shape	-Mesial and Distal Marginal Ridges -Palatal Ridge -Mesial and Distal Palatal Fossas -Incisal Ridges and tips
Distal / Mesial	-	-	-Mesially, the mesial incisal ridge is visible
Root	1 root	1 root, longer in relation to crown than CI	1 root, longest in all teeth
	Widest Mesiodistally	MD and BL almost the same	Widest Buccolingually

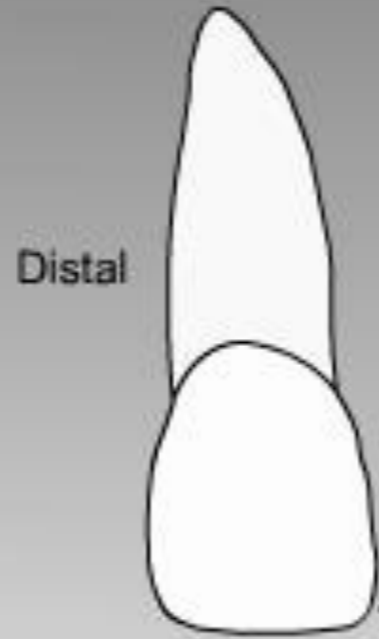
Permanent Maxillary Right Central Incisor (11)



MAXILLARY ANTERIOR

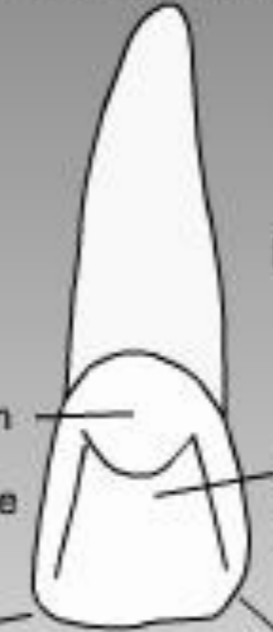

Labial view



Distal

Palatal/Lingual



Distal

Mesial

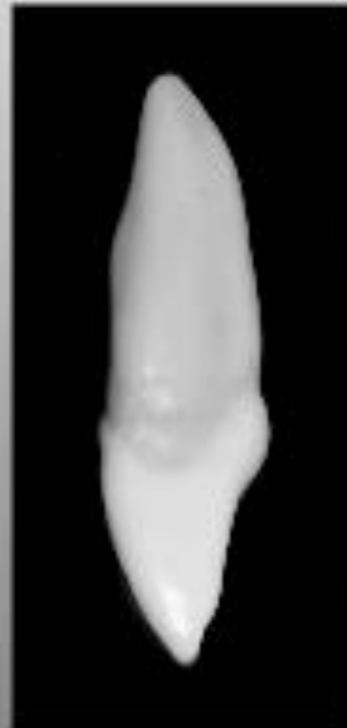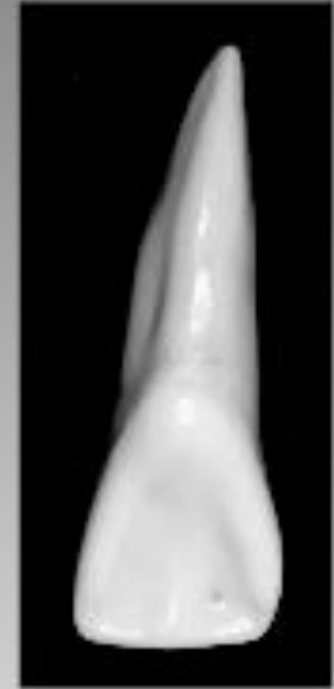Cingulum

Marginal ridge

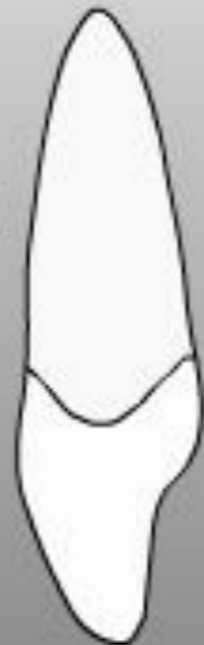Lingual fossa

Mesioincisal angle approx. 90°

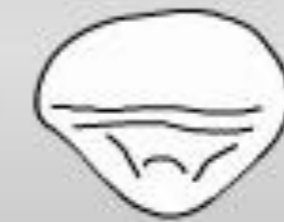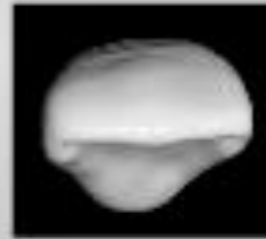
Distoincisal angle rounded



Labial

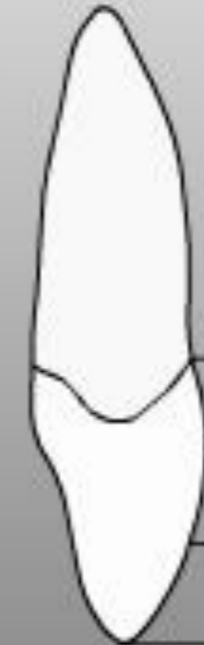

Mesial view



Incisal view

Palatal/Lingual



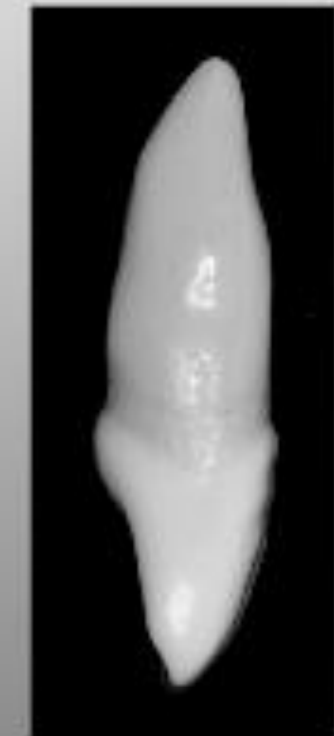Labial

Cervical third

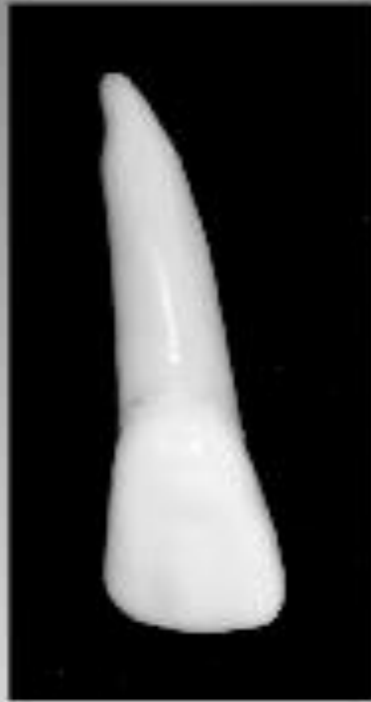Middle third

Incisal third

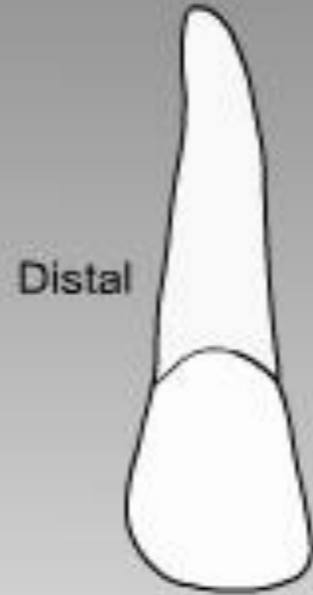
Distal view



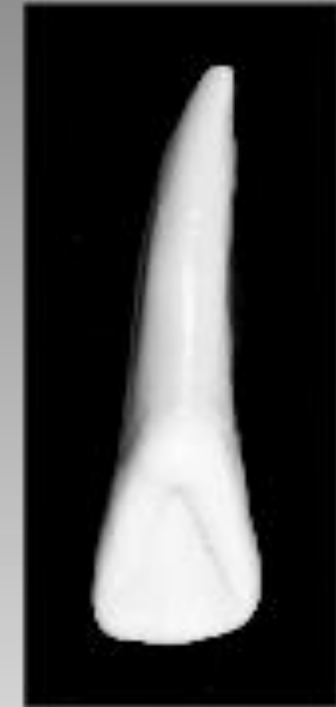Permanent Maxillary Right Lateral Incisor (12)



Labial view

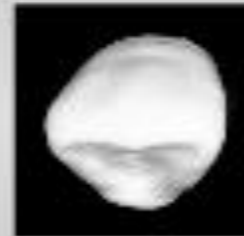
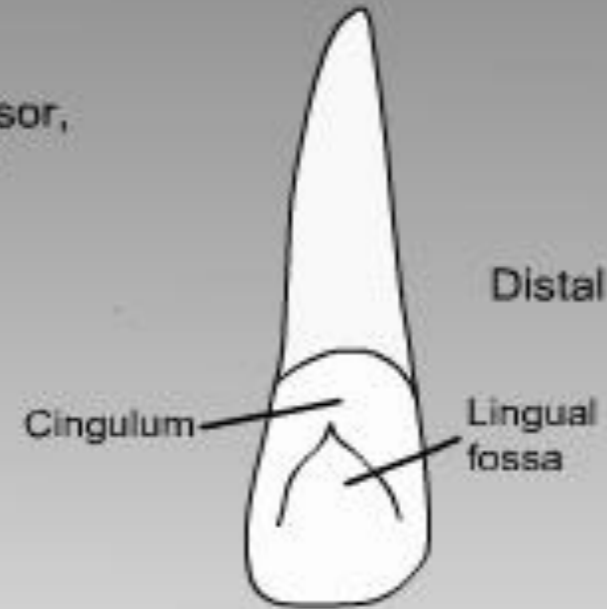


Palatal/Lingual view

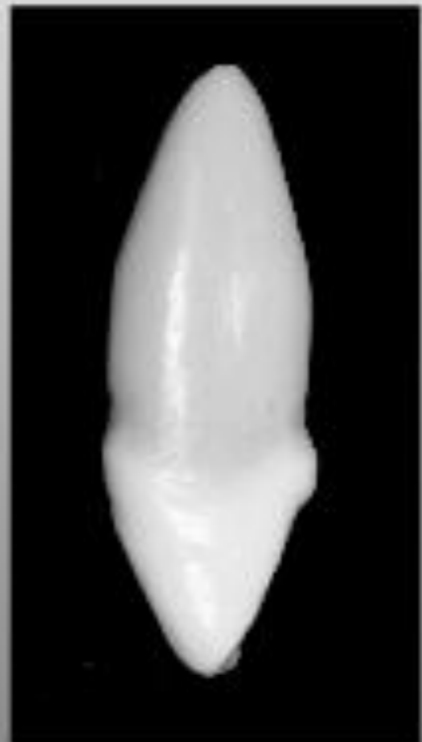

Smaller than central incisor,
except in root length

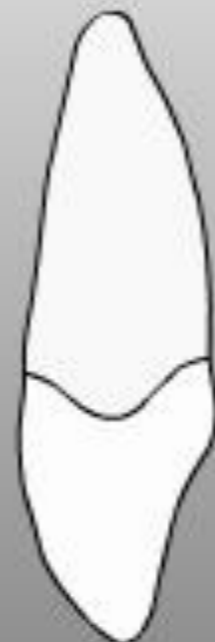Mesial



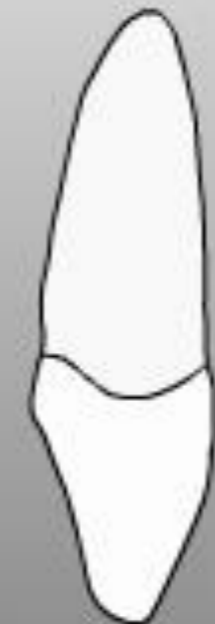Incisal view



Labial



Palatal/Lingual



Mesial view

Distal view

MAXILLARY ANTERIOR





MAXILLARY ANTERIOR

Permanent Maxillary Right Canine (13)

Labial view

Palatal/Lingual view

Distal

Mesial

Distal

Large cingulum

Marginal ridge

Lingual ridge - divides lingual into mesial and distal lingual fossae

Bell shaped

Incisal view

Labial

Labial

Mesial view

Palatal/Lingual

Distal view



DENTISCOPE.ORG



ASK@DENTISCOPE.ORG



DENTISCOPE



DENTISCOPE