Periodontal ligament

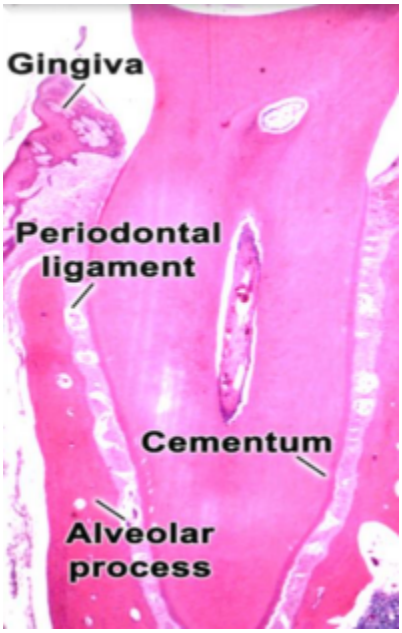

- PDL is a dense fibrous C.T, occupies periodontal space.
- It provides the attachment of the teeth to the surrounding alveolar bone.
- In x-ray It appears as a radiolucent area.
- Above the alveolar crest, PDL is continuous with the gingiva, this continuity with the gingiva is important when considering the progression to periodontitis from gingivitis.
- At the apical foramen, it is continuous with the pulp, this also contribute in the extension of pulp diseases to the PDL.

Q:Why is it referred to as a ligament ?

because the main component of PDL is collagen bundles .

Q:Ortho treatment depends on movement of teeth and it is related to 3 structures :

1. Alveolar bone
2. Cementum
3. Periodontal ligament

The periodontium :

1- PDL
2- Gingiva
3- Cementum (calcified)
4- Alveolar bone (calcified)

Thickness of the PDL : The thickness of PDL depends on :

1-The person's age – Normally thickness ranges from 0.15 – 0.38 mm, with its thinnest portion around the middle third of the root, indicates that the fulcrum of tooth movement. **PDL of permanent teeth is narrower than in deciduous teeth.**

- In young teenagers = 0.21 mm
- In 32-52 year= 0.18mm.
- It decreases to 0.1 mm in old age, this happens most likely as a result of the deposition cementum and bone **especially with mandibular canine (because of the area and the thickness of the alveolar bone)** → high incidence of fracture of tooth or even bone .

Q: explain the difficulty in extraction of mandibular canine in old age ?

because of the limited thickness of PDL due to deposition of cementum and bone .

Any tooth subjected to trauma might result in ankylosis (less amount of PDL)

Done By :
Sima Habrawi

2. Stage of eruption

3. Function of the tooth: it is thicker in functioning and in areas of tension than in non-functioning teeth(embedded teeth or impacted teeth , a tooth with no antagonist) and areas of compression.

Development of PDL: Origin Dental Follicle

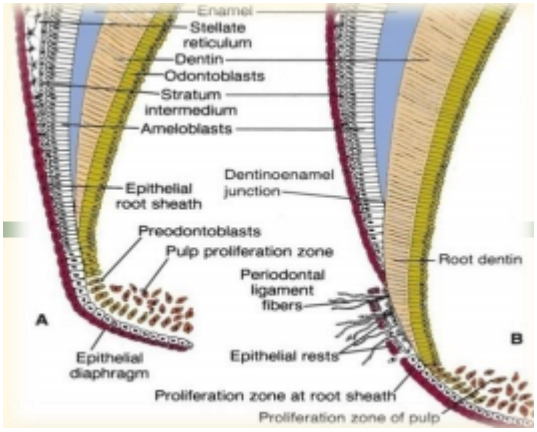

Ectomesenchymal cells give arise to:

(1) Cementoblasts- on the root
(2) Fibroblasts - periodontal ligament.
(3) Osteoblasts- alveolar bone.

Developmental anomalies : Enamel Pearl (tooth is vital- no caries or pulp diseases)

- **Location:** near CEJ (radioopacity at the bi or tri furcation – in some cases surrounded by radiolucency)
- **Process of formation:** failure in the detachment of the epithelial root sheath from radicular dentin, some cells of IEE still having the ability to produce enamel in these regions.(no cementum in this area so no fibers attached to this area , once this area is subjected to gingivitis or perio. pocket → the bacteria will accumulate in this area and a faster progression of the disease)
- **Significance**: the area more prone to periodontal diseases.(why ?)

A: it is a devp disturbance that happens during root devp, IIEE fails to detach in some areas from radicular dentin and has the ability to secrete Enamel so collagen fibers will not attach in this area → in case of gingivitis it will progress to a perio pocket.

Both pulp stones and E. pearls appear radiopaque but they are different in their location . (e. peal is attached to the tooth , pulp stones are found inside the tooth)

Enamel pearl affects the interradicular fibers.

Cementum will not form if epithelial cells are in contact with dentin.

Q:What are the cases that affect the continuity of the periodontal fibers attachment ?

Enamel pearls or late detachment of the IEE fromradicular dentin which will prevent cementum from forming in this area.

Done By :
Sima Habrawi

Development of principal fiber groups:

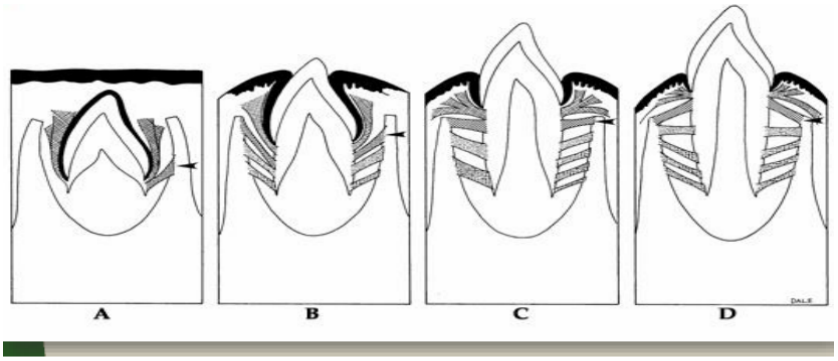

Example; The group of *alveolar* crest fibers *(arrowheads)*, first forming in A & B initially oblique , then horizontal (C), and then oblique again (D).

All groups are firstly formed in **oblique direction** then they changed with the progressing of tooth eruption until they take their specific direction. **The bundles gradually thicken after the teeth have been functional.**

Q:Do all fiber groups form initially with their correct orientation ?

A: NO , they all form in an oblique direction then change with the progressing of tooth eruption until they take their specific orientation.

Q: which group of fibers doesn't change their orientation? Oblique

Q: Does the apical group form when the tooth is functional or after ? the apical fibers **form after the tooth becomes functional** (recall : the apical foramen takes 3 years to close after the tooth is formed)

T/F : when the tooth erupts and reaches the occlusal plane ; all the groups of the PDL are formed ? False , the apical fibers are missing.

Q: Arrange the fiber groups according to their formation time ?

1- Alveolar crest
2- Horizontal
3- Oblique
4- Interradicular
5- Apical

NOTE : the last group of fibers to develop is the apical group .

Why PDL is a Specialized Tissue ?

1. It is different from other types of c.t. by: The principal collagen fibers have a characteristic orientation.

2. Similar to fetal tissue by:

- Types & amounts of collagen fibers
- Rich with Oxytalan fibers (immature elastic fibers)
- Rate of turn over is very fast
- Cellular and rich with ground substance, b.v, & nerves.

3. Its' special origin & location.

4. Has cells concerned with dental tissues formation.

Done By :
Sima Habrawi

Functions of the PDL:

1. **Supportive:** collagen fibers and B.V. withstand the masticatory forces. The collagen fibers act as an attaching apparatus between cementum and alveolar bone.
2. **Form, maintain, & repair:** cementoblasts, fibroblasts, osteoblasts.
3. **Nutritive:** through its B.V.
4. **Sensory:** the nerves provide the proprioceptive mechanism to detect an application of small forces.
5. **Homeostatic mechanism:** PDL cells have an ability to resorb and synthesize ECM of the PDL & bone. **The cells on bone side are more active than on cementum side (since bone is vascular) . The cells of PDL are turned over, old cells are replaced by new cells from progenitor cells.**

There are changes in tissue quality if the balance between synthesis and resorption is disturbed. For example: If there is **deficiency of vitamin C or protein (scurvy)** , the synthesis of collagen is reduced→ So there is a progressive destruction and loss of ECM, hence there is a loss of attachment between the bone and tooth.

orthodontic treatment is possible because PDL continuously respond and change.

Note : In case of implant , it is attached to the bone by **Osseo integration** (depends on osteoblast and osteoclast) , And they study occlusion very carefully since there is no PDL , so there is no cushion against occlusal forces. The implant has rough surface to provide good attachment of the tooth to the bone.

NOTE : When you chew on a hard object you directly open your mouth due to proprioceptors .

PDL Fibers :

I. Collagens:

- The predominate collagens are Types I, III , & XII. (1 , 3 , 12)
- Other types - IV ,V,VI,VII are also present. (4,5,6,7)

Most collagen fibrils in the PDL are arranged in bundles (5µm diameter).

Those bundles are running between the tooth and bone represent the principal fiber bundles. They cross the entire width of PD space in a **wavy course (to give some flexibility to withstand masticatory forces otherwise with any force the collagen fibers will tear)**, branch and join the other to form network.

- **Type III -**found near alveolar bone, around B.V & nerves.
- **Type XII-** bind collagen fibrils (to help in forming bundles) & to ECM.

Q:Most important collagen fiber is type 1 ? because it is the only type that forms bundles.

Q: the 2 structures that help the fibers in forming the attachment apparatus are ? cementum and alveolar bone

NOTE : In case of hypophosphtasia – no alkaline phosphatase → no cementum → early exfoliation of teeth (fibers will not be able to attach to dentin since there is no cementum)

Done By :
Sima Habrawi

Sharpey's fibres: secreted by fibroblasts found in both cementum and bone

- Each end of a principal fibres is embedded into bone or cementum. The embedded part of the fibres bundle is referred to **Sharpey's fibres.**
- Each Sharpey's fiber is composed of numerous collagen fibrils, either partially or fully mineralized.
- It has been estimated that there are **30000 fibers attached to cementum per mm2.**
- Sharpey's fibers entering the alveolar bone are less numerous & thicker than in cementum. In cementum they are more and thinner .
- In some regions of alveolar bone Sharpey's fibers cross all its width and called **transalveolar fibers.(because the bone is thin in this region – alveolar crest region)**

II. Oxytalan fibers :

- Oxytalan fibers are type of elastic Oxytalan fibers.
- Oxytalan microfibrils have similar fibronectin structure, formed by fibroblasts.
- Extend from cementum **or** bone to the walls of B.V. and lymphatics.
- The orientation of these fibers is in an axial direction, while near the root apex - they form a network.
- Function: To support vessels & regulate vascular flow.
- Very difficult to identify by H & E

Type of fiber	Location	Function	Notes
Collagen	From cementum of the tooth to the alveolar bone	Type 1 – forms bundles Type 3 – found near blood vessels and nerves Type 4 – binds fibrils together to form bundles and binds fibrils to ECM.	Formed by fibroblasts
Oxytalan	From cementum or bone to the walls of BVs and lymphatics	Support vessels and regulate Blood flow	They are oriented in an axial direction and near the root apex they form a network

Done By :
Sima Habrawi

Groups of fiber bundles found in PDL & Gingiva:

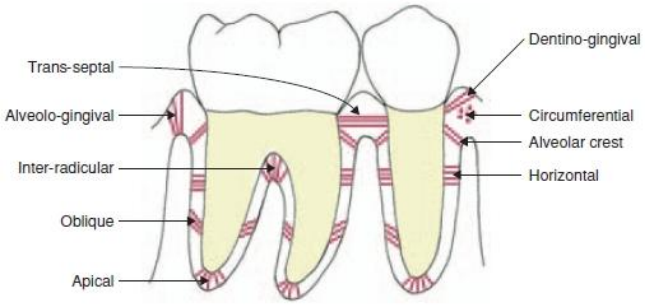

A. **Principal fiber groups (alveolodental ligament): from cementum to alveolar bone**
   1. Alveolar crest group
   2. Horizontal group
   3. Oblique group
   4. Apical group
   5. Interradicular group

Q: when do the fiber groups start exactly ?

Below the epithelial attachment which is below the gingival sulcus .

Alveolar crest group:

- Originates from the alveolar crest and funs out to insert into cervical cementum at various angles.
- Function: Resist extrusive, intrusive, tilting and rotational forces.

Horizontal group :

- Originates from the alveolar bone proper (the first layer of the alveolar bone that forms the socket of the tooth) apical to the alveolar crest group and inserts into the cementum horizontally.
- Function: resist tilting and rotational forces.

Oblique fiber group :

- Originates from alveolar bone proper and extends apically to insert into the cementum (attachment to bone is higher than cementum) in an oblique manner.
- Located apical to the horizontal fiber group.
- They are the **most numerous in the PDL, covers the two –thirds of the root**.
- Function: resist intrusive forces (which try to push the tooth inward) as well as rotational forces.

Apical fiber group:

- Radiating from the apical region of the cementum to insert into the surrounding alveolar bone proper. <u>The neurovascular bundle courses between these fibers to enter the apical foramen.</u>
- Function: resist extrusive forces (which try to pull the tooth outward) and rotational forces.

Interradicular fiber group : usually accompanied by transalveolar fibers

- Found between the roots of multirooted teeth and running from the cementum into the crest of the interradicular septum.
- Function: resist intrusive, extrusive, tilting, and rotational forces.

Q: name the fibers groups that can be seen in maxillary first premolar ? All + interradicular

With mandibular first premolar → all **expect interradicular (since it has only one root)**

Done By :
Sima Habrawi

Q:During extraction of teeth , what is the force and which fiber groups resist this force ?

A: extrusive , Interradicular + Apical + alveolar crest fibers

Q: which group of fibers will resist the extraction of a mandibular first premolar with periodontal pocket?
A:only apical fibers

Q: what is the **main group** of fibers that resists intrusive forces , why ? oblique , because it covers 2/3 of the root

TYPE OF FORCE	FIBER GROUP
ROTATIONAL	Alveolar crest Horizontal Oblique Apical Interradicular
INTRUSIVE	Alveolar crest Interradicular oblique
EXTRUSIVE	Alveolar crest Interradicular Apical
TILTING	Alveolar crest Interradicular Horizontal

Q:What are the common features of alveolodental ligament ? They all resist forces , made from collagen type 1 , extend from alveolar bone to cementum

B.**Fiber groups of gingival ligament:** provide support for the marginal gingiva and interdental papilla. They resist gingival displacement during mastication. They **maintain gingival integrity.**

1. Dentogingival
2. Alveolargingival
3. Circular
4. Dentoperiosteal
5. Transseptal

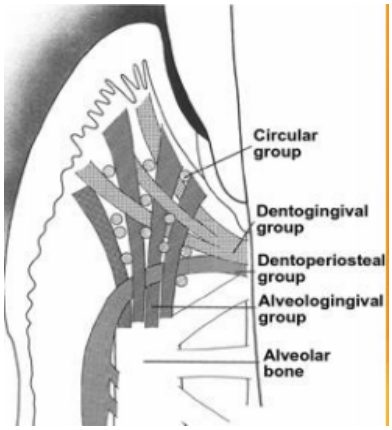

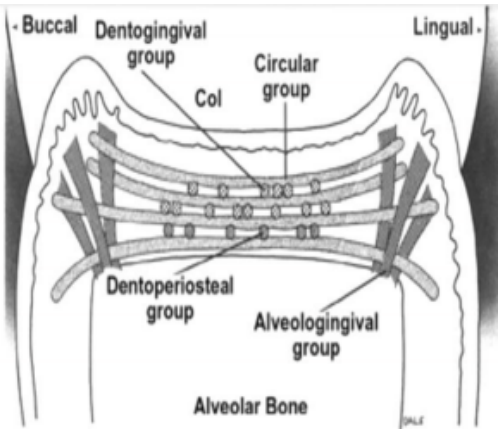

1. Dentogingival group: extending from cementum, apical to the epithelial attachment, to the gingiva. This group has one mineralized attachment to the cementum.

Done By :
Sima Habrawi

2. Alveologingival group: extends from alveolar crest to the marginal gingiva. Attach the gingiva to the alveolar bone, has one mineralized attachment to the bone.

3. Circular group: located in the lamina propria of the marginal gingiva. It encircles the tooth.

4. Dentoperiosteal group: extends from the cementum, across the alveolar crest, insert to the periosteum of alveolar bone. They protect the deeper PDL groups.

5. Transseptal fibers group: extended from the cementum of one tooth to the cementum of the adjacent tooth. They form interdental ligament that connecting all the teeth of the same arch. Function: resist rotational forces and thus hold the teeth in interproximal contact.

Note: The major cause of post-retention relapse of ortho treated teeth is this group. Prolonged retention period following ortho. treatment is needed for reorganization of this group to have stable teeth positions.

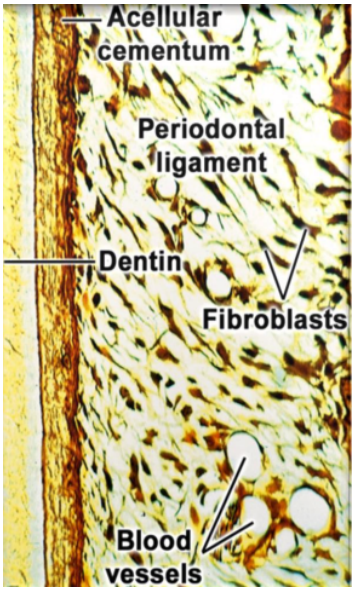

NOTE : Those fiber groups are the first line of defense .

All of those fibers have only one calcified attachment except :

- Circular group – no calcified end tain
- Transseptal fibers – 2 calcified ends (similar to PDL fibers)

Q: what are the fibers that are attached to the alveolar crest bone?

The alveologingival fibers (related to gingiva) and the alveolar crest fibers (related to PDL)

Ground Substance:

G.S. composed of 70% water, and adehsive proteins (**glycoprotein** ex fibronectin – binding sites to cells , collagen and GAGAs and proteoglycans protein core + attached GAGs). All components secreted by **fibroblast cell.**

What is the importnac eof adhesive proteins ? they make the connection between different elements of the CT (cells , fibers etc)

The main types of GAGS are:

1- hyaluronic acid (free not connected to any protein)	**2- dermatan sulfate (interact mainly with collagen type I)**
3- chondroitin sulfate (attaches to collagen type 2)	**4- heparin sulfates (related to basement membrane)**

G.S. functions are:

1- ions & water binding,	2- control of collagen fibrillogenesis
3- binding of growth factors	4- tooth support & eruption
5- inhibitor to mineralization of PDL	6- promote attachment mainly by fibronectin

Done By :
Sima Habrawi

PDL CELLS :

Fibroblasts : The predominant cell – the only cell that has double function

- fusiform shape
- origin : undifferentiated ectomesenchymal cells
- rich with a protein synthesis organelles
- a well-developed cytoskeleton for changing their shape & migration.
- They show cell-to-cell contacts of the adherens and gap junction types.
- They aligned along the fiber bundles and have extensive processes that wrap around the bundles. (responsible for the turn over of those bundles)
- Fibroblast is capable of synthesizing. They phagocytized collagen, exhibit lysosomes- vacuole which contain collagen fragments.
- Polarized since the secretion is form one side only

During periodontal disease: the loss of collagen may be due to rapid rate of breakdown or slow rate of synthesis.

Normally fibroblasts secreted **matrix metalloproteinases- MMPs** (which degrades collagen), & **tissue inhibitors of MPs (TIMPs)** (high in normal conditions – opposite function to MMps).

More MMP → breakdown of collagen (ex: perio diseases)

This provides the use of drugs that have a similar activity to TIMPs to combat periodontal disease.They might also add hyaluronic acid to increase adhesion

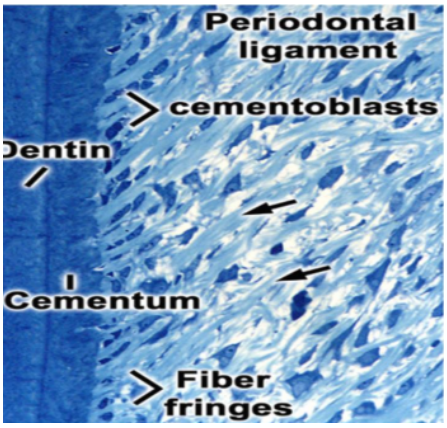

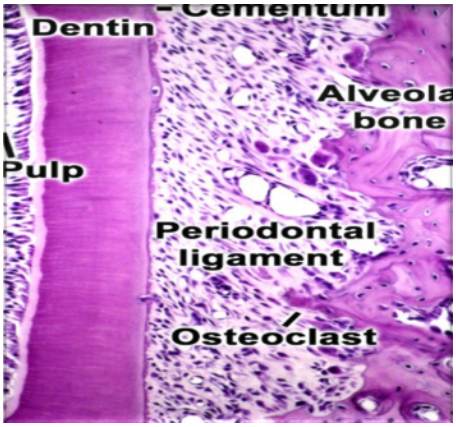

Other synthetic & resorptive cells :

- Adjacent to the **cementum** are **Cementoblasts & cementoclasts.**
- Adjacent to the **alveolar bone** are osteoblasts & Osteoclasts.

These cells are technically within PDL but they are associated with the hard tissues of periodontium.

Done By :
Sima Habrawi

Epithelial rests of Malassez: the only cell that is different in it's origin : enamel organ while all other PDL cells come from the dental sac or follicle + they are the only group of cells surrounded by basal lamina

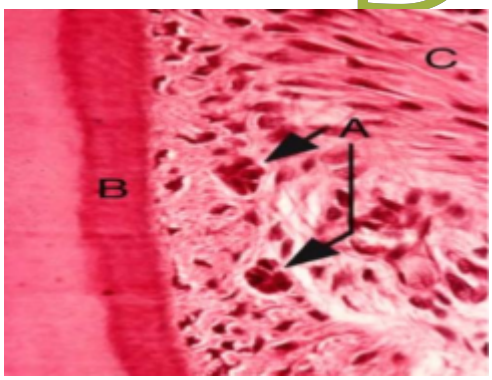

- They are remnants of the epithelial root sheath.
- Occur close to the cementum as cluster , network or strands of cells that surrounded by a basal lamina.
- Easily recognized in H&E sections. (takes a deep stain since they are non active cells)
- No function in normal conditions. But if there is any pathological changes, they can undergo rapid proliferation to form **periapical cyst**.
  Periapical cyst : untreated pulpitis → pulp necrosis → spread of disease through apical foramen → proliferation of cells and formation of periapical cyst .
  With age those epithelial rests of malasses might get calcified and form cementicles within the PDL.

Q:The cells that have the ability to divide and stay ? stem cells

Undifferentiated ectomesenchymal Cells or progenitor cell:

They are located as perivascular, consider a pool of new cells (fibroblasts, osteoblasts, & cementoblasts).

When cell division occurs, one of the daughter cells differentiates into functional type while other cell retain its capacity to divide in the future.

Mast cells and macrophages:

- Mast : contain numerous cytoplasmic granules and found during inflammation.
- Macrophages : are derived from monocytes and has kidney shaped nucleus , help in phagocytosis of dead cells and secreting growth factors (which help to regulate the proliferation of fibroblasts).

Done By :
Sima Habrawi

Blood & lymphatic Supply:

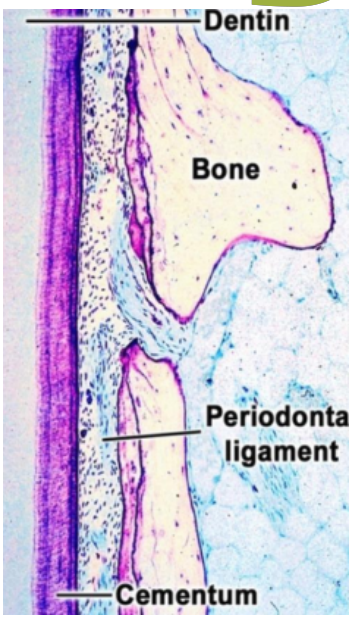

The blood supply of PDL is derived from:

1- Interalveolar arteries passing interdental alveolar process to the PDL.
- They are more in the posterior teeth, mandibular teeth, & gingival 3rd + apical 3rd of PDL.
- In healing of extraction wounds, blood clot formation is more rapid in its gingival & apical areas (because they have more interalveolar arteries)

2- Blood vessels from the gingiva.

3- Blood vessels entering PDL from the apical area.

Explain why infection spreads easily towards the PDL? Because of the perfuse blood supply of the PDL.

PDL veins: do not usually accompany arteries, they pass through alveolar walls, venous network is present at the apical portion of PDL.

Lymphatic vessels: follow venous drainage.

lymphatics drain to submandibular lymph nodes, except for the mandibular incisors drain to the submental lymph nodes

Two Specialized features of PDL \ B.V are present:

1- Cervical plexus of capillary loops : between PDL vessels & gingival vessels may related to provision of dentogingival seal.

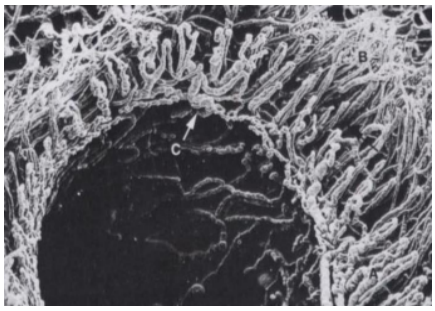

2- Fenestrations (thinning of endothelium) of PDL capillaries (arrows) : The diffusion & filtration capacities are increased with fenestrations which needed for high rate PDL turnover.

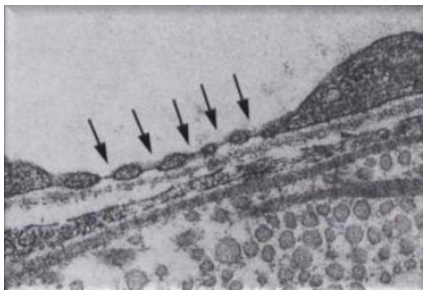

Done By :
Sima Habrawi

Nerve Supply:

- Autonomic: associated with B.V. of PDL, they control B. flow.
- Sensory: are myelinated or unmyelinated, transmits sensation as :

A. **Nociception :**perception of a painful stimulus by stimulation of specialized nerve receptors.
B. **Mechanoreceptor:** a sensory receptor that responds to pressure, vibration, or any mechanical stimulus. They transmit proprioceptive sensations via the **trigeminal pathways, which give a sense of localization when the tooth is touched.**

But in case of implants the patient can't detect increase in pressure (since there is no PDL) so you need to be careful with occlusion .

1- **Free endings :** tree-like ramifications, most frequent type, extended to cementoblasts. They are nociceptors (pain) & mechanoreceptors (pressure)
2- **Ruffini's ending:** found around root apex, ramifies to form a flower spray- type ending. Function as mechanoreceptors.
3- **Coiled ending:** at the mid-region of the PDL.
4- **Encapsulated spindle-type ending:** less frequent type, at the root apex. They convey pressure.

FUNCTION	TYPE OF NERVE ENDING
PAIN	Free nerve ending
PRESSURE	Rafini , encapsulated , free nerve endings

Root apex : rafini + encapsulated **Root side : free nerve endings**

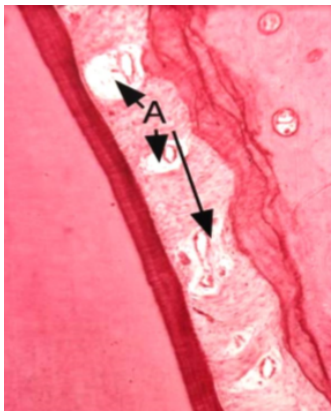

Interstitial spaces :

- regions of loose CT located between PDL bundles that extend along the entire width of the PDL
- Contain fibroblasts, B.V, and nerves, responsible for providing nutrients to PDL, cells of the cementum, & alveolar bone.
- Appear lighter during sections since they are made from loose CT .

Cementicles :

- calcified bodies found in PDL formed above dead cells .
- Some are formed from the calcification of **epithelial rests of Malassez** .
- **Types:** Cementicles may be free in the PDL, or attached to the surface of cementum, or embedded in the cementum.

→ epithelial rests of malassez might either form pathological lesions or cementicles

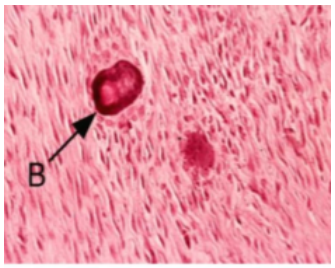

Done By :
Sima Habrawi

Periodontium& function:

→ **When the periodontium is exposed to increased function (ex : teeth extraction on one side of the mouth will increase the work load and the function of the other side in the mouth) , leads to:**

1. Width of PDL- increases by 50%,
2. Principal fiber bundles increase in thickness.
3. Alveolar bone becomes thick.

→ **Non-functional periodontium (ex : teeth that aren't in correct occlusion or if they lose their antagonist)**

1. The ligament narrows,
2. Fiber bundles decrease in number & loose the organization
3. The trabeculae of bone become fewer

Aging of PDL :

(1) Decrease in cell number & activity (less ability to repair itself)
(2) PDL structures can undergo drastic changes as a result of periodontal disease.
(3) In aging, scalloping occur in cementum and alveolar bone. Fibers are attached to the peaks of these scallops rather than over the entire surface.

CLINICAL CONSIDERATIONS:

(1) Width of PDL varies with age & function.
(2) PDL contains precursor cells.
(3) Appropriate therapy of periodontal disease can result in repair of periodontal defects.

Ex: For Healing in cases of deep perio pockets , **guided membrane regeneration** (insert a membrane in the deep pocket) is used to allow the formation of PDL from precursor cells . if you don't put the membrane the gingiva is attached to the cementum directly.

(4) PDL provides success of reimplantation of an avulsed tooth.
(5) The ligament cells are capable of remodeling PDL and bone, when functional forces are altered.
(6) The balance of formation and maintenance of C.,B.,&PDL is under control of cells. Any disturbance can lead to abnormal conditions, as **with ankylosis of teeth often associated with osteoclast defect**. Also **lack of cementum formation lead to exfoliation of teeth as in hypophophatasia**. (no sharpeys fibers embedded in cementum – no attachment of PDL)
(7) Role in orthodontic treatment.

Done By :
Sima Habrawi

Role of PDL in orthodontic treatment :

Two possible ways are applied during ortho treatment ;

(1) **bodily movement** (when the tooth show pressure areas on one side of the root and tension areas on the other side)
(2) **Tipping movement** (crown & root in opposite directions producing pressure & tension zones on either side of the root).

On the side under tension :

- PDL become wider, fiber bundles are stretched , new Sharpey fibers, & new bone formation.
- Fibroblasts synthesize interleukin-1 & 6 which stimulate MMP. Degradation of ECM by MMPs facilitates cell proliferation and capillary growth.
- Osteoblastic activity is evident, part of newly synthesized collagen will be incorporated into osteoid & some into PDL.

ON THE TENSION SIDE OF ORTHO MOVEMENT → Explanation :

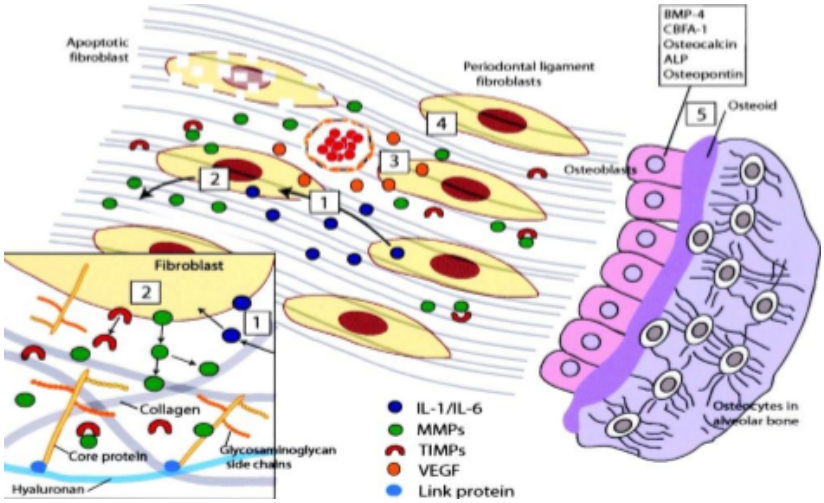

1. **[BLUE]** Fibroblasts secrete cytokines (interleukin 1 & 6)
2. **IL 1 / 6** will stimulate other fibroblasts to secrete MMPS. **[GREEN]**
3. Other fibroblast cells secrete vascular endothelial growth factor VEGF **[ORANGE]** to form capillaries and provide nutrition.
4. MMPs degrade ECM and allow the formation of new fibroblasts .
5. Osteoblast secrete osteoid to allow formation of new Sharpey's fibers

Only osteoblast and fibroblast work on the tension side

Q: Are all synthetic cells involved in the tension side ?

A: NO , the Cementoblasts cells are not involved

Done By :
Sima Habrawi

On the side under pressure:

1. With mild forces; PDL become narrower, vascular activity is low, fibroblasts synthesize interleukin-1 &6, act to up-regulate RANKL & MMP expression by fibroblasts and osteoblasts.

Osteoblast-derived MMPs degrade osteoid, while MMPs produced by fibroblasts degrade ECM of PDL. RANKL stimulates the formation and function of osteoclasts.

2. With heavy forces, there is degenerative changes, normal osteoclasts are absent , there is edema , obliteration of B.V, & root resorption.

Q: If a tooth is moved from mesial to distal with bodily movement , what are the changes that occur at the **distal side of the tooth** ?

A:Compression side .

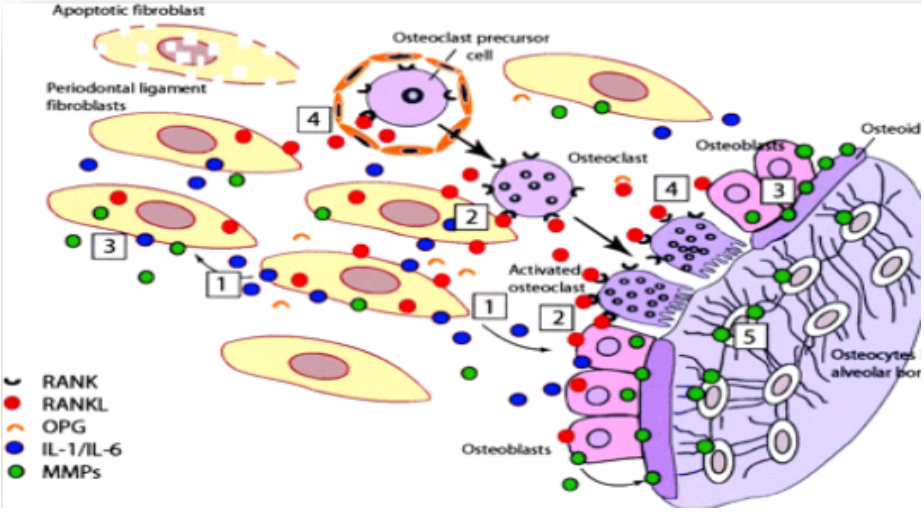

1. Fibroblasts secrete interleukin 1 and 6
2. IL 1 & 6 stimulates fibroblasts and osteoblasts to secrete RANKL & MMPs
3. Osteoblasts degrade the osteoid by expressing MMPs not the osteoclast while fibroblasts degrading ECM
4. RANKL helps in the differentiation of the precursor of the osteoclast
5. osteoclast and attach to the surface to resorb mineralized bone

.

NOTE :

- The area you move from → tension (bone formation)
- The area you are going to → compression (bone resorption)

" I moved from Tennessee to go to combodia "

EX: tooth move bodily from distal to mesial then the distal is tension side and mesial is compression side

- PDL resorbed by → fibroblasts
- Osteoid resorbed by →osteoblasts
- Mineralized bone resorbed by → osteoclasts

Done By :
Sima Habrawi

DENTISCOPE.ORG

ASK@DENTISCOPE.ORG

DENTISCOPE

Done By :
Sima Habrawi