CRASH COURSE IN PERIODONTICS

DENTISCOPE

WWW.DENTISCOPE.ORG

DONE BY : SIMA HABRAWI

EDIT BY : HAIF ALQAHTANI

DENTISCOPE 2020

Table of Contents

Anatomy and basics

- Periodontium = tissues that surround the teeth [gingiva + PDL + alveolar bone + cementum]
- Attachement apparatus = alveolar bone + cementum + PDL

Masticatory mucosa	Lining mucosa	Specialized mucosa
Gingiva + hard palate	Mucosa lining the oral cavity – lips and cheeks	Dorsum of the tongue

Gingival anatomy:

- **Marginal gingiva [GM] :** terminal part of the gingiva surrounding the teeth like a collar forms the soft tissue wall of the sulcus
- **Free gingival groove [FGG] :** a line separating between the gingival margin and the attached gingiva
- **Gingival sulcus:** V shaped space bounded by the tooth from one side and the sulcular epithelium on the other side. Normal depth= [1-3 mm]
- **Muco gingival junction [MGJ]:** seperates between the attached gingiva and the oral mucosa
- **Attached gingiva** : from the FGG to the MGJ
- **Keratinized gingiva** : from GM to MGJ

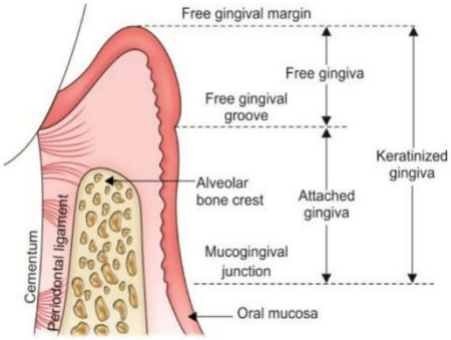

The interdental gingiva occupies the gingival embrasure, which is the interproximal space beneath the area of tooth contact. If there is no interproximal contact between the teeth the interdental papilla disappears.

Gingival epithelium:

1- **Outer oral epithelium** – covers the part of the gingiva u see – incomplete type of keratinization [parakeraatinized] – has 4 layers from top to bottom [stratum corneum- stratum granuloseum- stratum spinosum – stratum basale]

2- Sulcular epithelium – non keratinized stratified squamous epithelium – from junctional epithelium to gingival margin – acts as a semi permeable membrane through which bacterial products pass into the tissue and gingival fluid passes into the sulcus

3- **Junctional epithelium** - non keratinized stratified squamous epithelium – formed by the union of oral epithelium with reduced enamel epithelium during tooth eruption
JE can form around implants
JE attaches to tooth by internal basal lamina and to the CT by external basal lamina
Dento gingival unit = junctional epitheium + gingival fibers

Gingival fibers:

1- **Gingivo dental:** from cementum in a fan like pattern on labial, lingual and interproximal surfaces
2- **Circular :** encircle the tooth like a ring
3- **Transseptal :** extends from cementum of one tooth to cementum another tooth

- **Stippling =** is seen in attached gingiva and center of interdental papilla – absent in infants appears at the age of 5 and disappears in eldery
- **Position of the gingiva =** where the gingival margin is in relation to the tooth
- **The PDL =** hour glass shape with the narrowest portion in the middle 3rd of the root

PDL fibers	
Oxytalan	**Principle fibers**
Immature elastic fibers around the walls of blood vessels	**Collageneous and arranged in bundles – wavey course** **In order of their development:** 1- **Transseptal fibers:** run from the cementum of one tooth to the cementum of the adjacent tooth over the alveolar bone [considered gingival fibers since they don't have bone attachment] **2- Alveolar crest fibers:** from cementum to alveolar crest [prevent extrusion and lateral movement] 3- **Horizontal fibers:** at right angles from cementum to bone 4- **Oblique fibers:** largest group – bare most of masticatory forces - from cementum obliquely to the bone in coronal direction 5- **Apical** : extend in irregular way from cementum to bone in apical region 6- **Interradicular:** from interradicular crest of multi rooted teeth to the cementum in a fan like pattern

- **Sharpey's fibers =** the terminal portions of the principle fibers that insert into the cementum and bone – once the sharpey's fibers enter bone or cementum they calcify greatly.

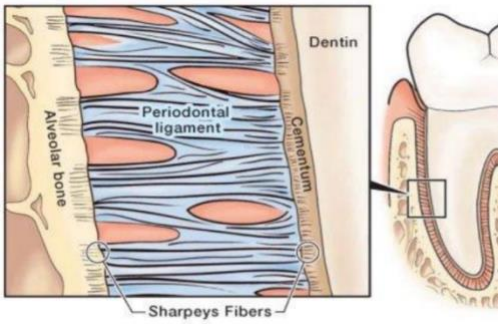

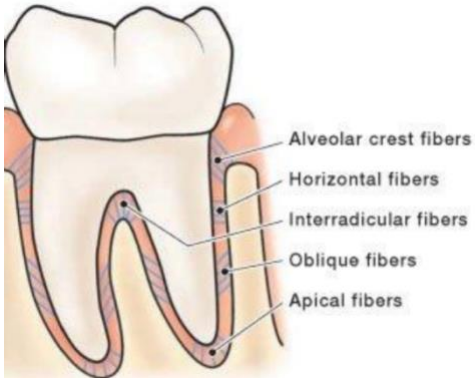

PDL functions:

- Physical : transmit occlusal forces to the bone + resistance to the forces (shock absorption)
- Formative + remodelling: PDL cells form + resorb cementum and bone
- Nutriton + sensory functions : supplies the cementum, bone and gingiva + nerve fiber transmit tactile, pressure, pain sensations

Cementum:

Primary = acellular – first that forms covers the cervical 3rd(formed before the tooth reaches the occlusal plane) – more calcified and has more sharpey's fibers

Secondary = cellular [cemnetocytes] - forms after primary cemntum and covers apical 3rd formed after the tooth reaches the occlusal plane – less calcified and less sharpey's fibers

Function of cementum:

1- Attachment for PDL fibers
2- Reperative tissue in case of root resorption
3- Functional adaptation : excessive cementum formation apically to compensate for incial and occlusal wear and mainatian occlusal plane

Alveolar bone: bone that surrounds the tooth in the mandible or maxilla

1- **Alveolar bone proper:** forms the socket wall - surrounds the root and gives attachment to the PDL fibers
2- **Supporting bone:** below the alveolar bone proper , consists of:
Buccal and lingual plates surrounding spongy bone

Cortical plates = thicker in the mandible and in the premolar molar regions

Bundle bone = bone next to PDL that has great number of sharpey's fibers radiographically appears as a white line called lamina dura

CEJ:

- **60-65% cementum overlaps enamel**
- **30% edge to edge**
- **5-10 % there is a gap**

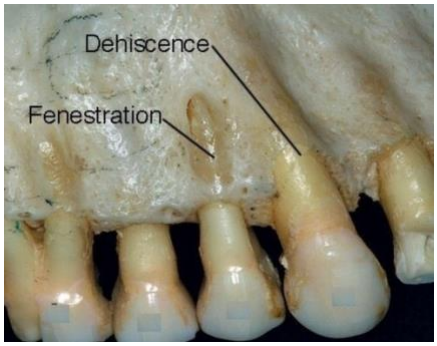

Ankylosis= fusion of cementum to bone without PDL

- **Fenestration =** isolated areas of the root that are denuded of bone **– intact marginal bone**
- **Dehiscence=** exposed root surface denuded of bone involves the marginal bone

Increased function→ increase in number and diameter of sharpey's fibers + increase in bony trabeculae number and thickness

Decreased function→ PDL becomes thinner [afunctional atrophy / disuse atrophy] +bony trabeculae decrease in number and thickness

Gingival & Periodontal examination

Perio probe is held in modified pen grasp

Walking stroke – move the perio probe up and down short strokes 1 mm apart from each other made inside the sulcus around the tooth circumference (the probe is not removed from the sulcus) – with each down stroke the probe touches the JE.

- **Pressure of the probe against the JE should be 25 grams**

Q: **how do you probe interproximal areas?** Slant the probe slightly do the tip extends below the contact area while the upper portion of the probe touches the contact area

- Healthy sulcus = 1-3 mm deep [JE above the CEJ]

Gingival clinical examination parameters				
Color	**Size**	**Contour**	**Shape / texture**	**Consistency**
Normal = coral pink **Color determined by :** Degree of vascularization + degree of keratinization + gingival thickness **** light to dark brown areas might be seen = racial pigmentation due to melanin pigmentation** **Pale Pink =** chronic inflammation → gingiva becomes fibrotic → increase in collagen and keratinization+ less vascularization → pink **Red =** acute inflammation More vascularization + less keratinization **Bluish purple =** cyanosis due to chronic inflammation and obliteration of gingival blood vessels	Cellular + intercellular components Change in size = sign of disease	**Normal =** scalloped knife edged **Disease:** **Margins-** Round / rolled enlargement Recession Clefts ; narrow slit like recession **Interdental papilla-** **Bulbous -** fills interdental embrasure but not pyramidal in shape **Blunted :** does not fill the interdental embrasure **Cratered:** Depression instead of peak in interdental embrasure	**Least reliable sign of gingival disease** **Normal =** smooth shiny gingiva	**Normal =** firm and resilient [bound to the underlying bone] **Disease:** **Spongy, soft and edematous** **[the side of the probe is easily pressed against the tissue]** **fibrotic → i**n chronic inflammation [very firm]

Exudation : inflammation → accumulation of neutrophils in gingival fluid → purulent exudate

Q: **how do you check for exudate?** Apply your index finger against the gingiva in a rolling motion toward the crown and look for anything that comes out

Bleeding on probing [BOP]:

- Bleeding on probing is an early sign of inflammation rather than changes in color
- Non inflamed sites do not bleed
- Walking stroke to test bleeding on probing
- Bleeding can be immediate or delayed [after 30-60 seconds]

Pocket = sulcus more than 3 mm can occur by coronal movement of gingival margin or apical movement of gingival attachment or both

- **True pocket =** periodontal destruction **occurs**
  A. **Suprabony/ supra crestal / supra alveolar** –bottom of the pocket is coronal to the alveolar bone – occurs with horizontal bone loss
  B. **Infrabony/ subcrestal / intra alveolar -** bottom of the pocket is apical to the alveolar bone – occurs with vertical bone loss
- **False pocket / pseudo pocket / gingival pocket =** gingival enlargement without periodontal destruction

Pocket depth [PD]= from gingival margin to bottom of the pocket – you record the deepest value for each surface

Recession: from gingival margin to CEJ

> **Positive recession** → there is actual recession [GM below CEJ]
> **Negative recession** → gingival overgrowth [GM above CEJ]
> **Zero** → GM is at CEJ

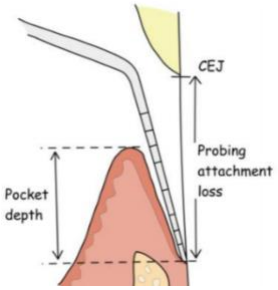

Clinical attachment loss : CEJ to JE

Pockets cannot be detected by radio graph → they are ST change

- **Gingival margin coronal to CEJ [false pocket] → CAL = PD – recession**
- **Gingival margin = CEJ → CAL = PD**
- **Gingival margin apical to CEJ [true pocket]→ CAL = PD + recession**

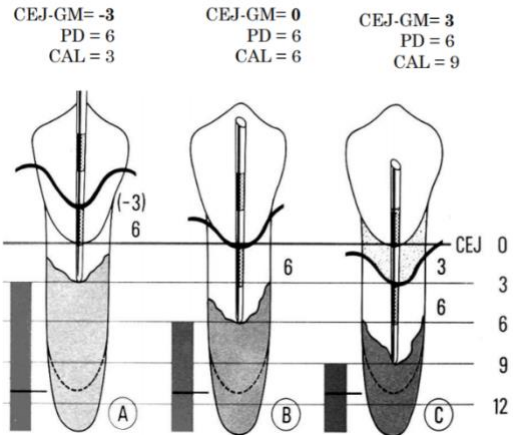

Q: how can you measure the width of attached gingiva?

You measure the pocket → then locate MGJ → then measure from MGJ to GM → subtract pocket depth from total gingival width.

Or use schiller's solution [potassium iodide which stains keratin] → gives you total width of gingiva

you can watch our video for : **HOW TO DETERMINE CLINICAL ATTACHMENT LOSS**
Web : **dentiscope.org** or YouTube channel : **Dentiscope** Or the link below:
https://youtu.be/L-fYRfvdyG4

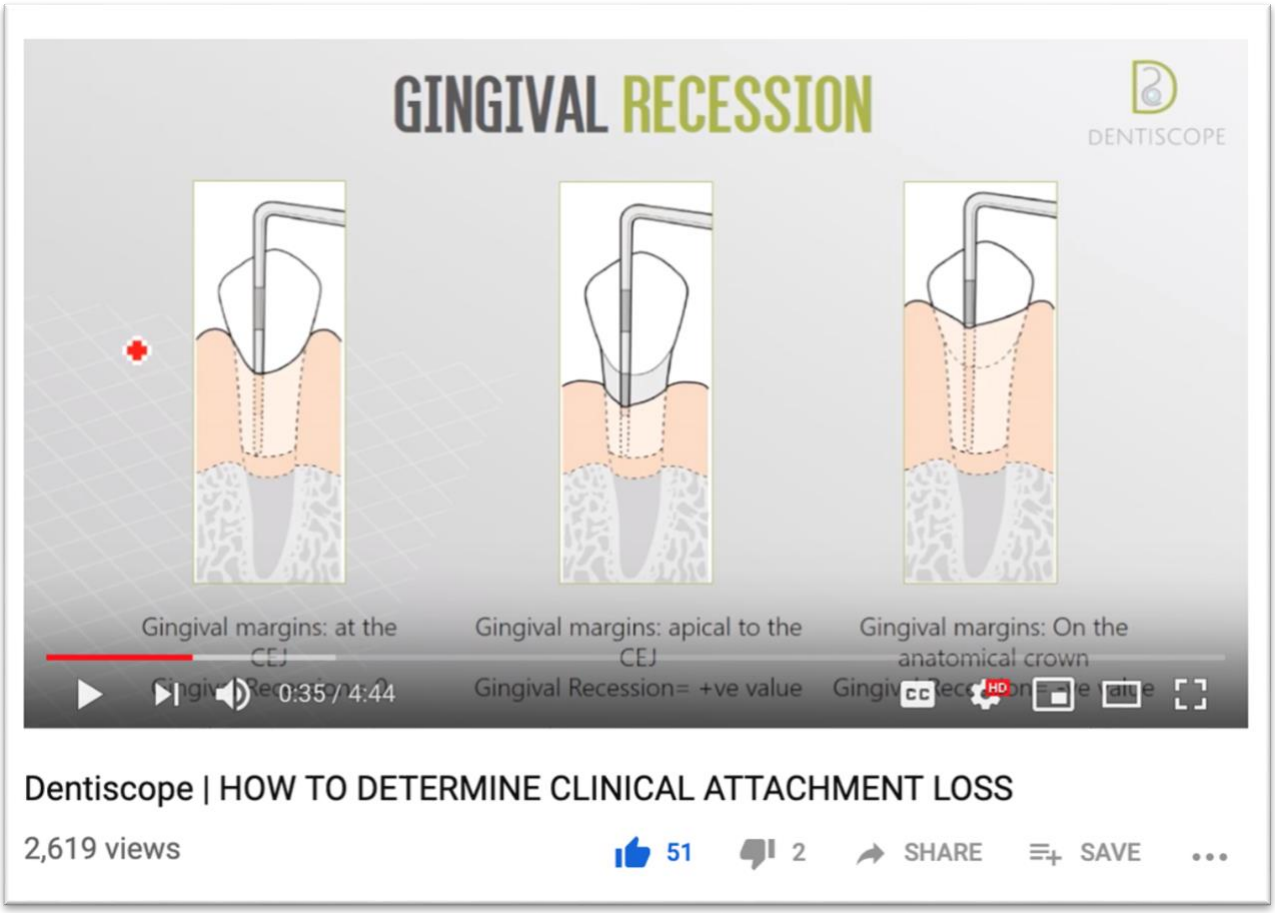

Q: **how can you locate the MGJ?** Pull the lip or check or push the lip coronally or push the adjacent mucosa coronally with a dull instrument

- Attached gingiva is widest in the anterior region and narrowest in the premolar region

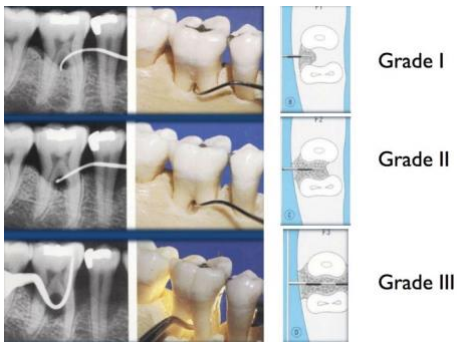

Furcation: assessed by curved probe [Naber's probe]

- **Class I →** horizontal loss of supporting tissue not exceeding 1/3 of the width of the tooth
- **Class II →** horizontal loss of supporting tissue exceeding 1/3 of the width of the tooth but not encompassing the total width of the furcation area
- **Class III →** horizontal through and through destruction of the supporting tissues in the furcation

Bone loss – greater than what it appears on radiograph

Upper molars → buccal + mesial + distal furcation entrances upper PM → mesial and distal
lower molars → buccal and lingual only

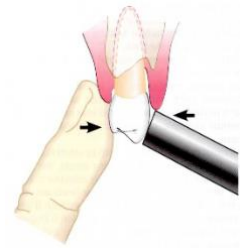

Mobility: tested by finger + end of mirror or ends of two mirrors

Abnormal movement usually occurs buccolingually

- Grade I →crown moves up to 1 mm in horizontal direction
- Grade II→ crown moves more than 1 mm in horizontal direction
- Grade III→ crown moves horizontally and vertically [easily displaced into the socket]

Q: how do u determine level of bone on radiograph? Line from b/w CEJ should be parallel to the line b/w bone crests and should be 1-1.5 mm away

- Horizontal bone loss → the 2 lines are parallel but the distance is more than 1.5 mm
- Vertical bone loss → the 2 lines are not parallel

Microbiology/ basic concepts

> **Obligate aerobes**: need oxygen to grow
> **Obligate an areobes**: cannot survive if there is oxygen
> **Facultative** : can grow with or without oxygen [s.mutans]
> **Microaerophile:** grows under low concentration of oxygen [P.gingivsalis]

- **Gram +ve bacteria** → thick peptidoglycan layer → stain purple
- **Gram -ve bacteria** → stain does not reach peptidoglycan layer → stains pink / reddish
- **Pathogen** = any agent that can cause disease
- **Virulence** = the degree or ability of a pathogen to cause disease
- **Commensalism:** bacteria benefit but host not harmed
- **Mutualism** : both bacteria and host benefit
- **Parasitism**: bacteria benefits and host is harmed
- **First bacteria to colonize the oral cavity in infants = s. salivarius and S.mitis**

Red complex = cause BOP

> P.gingivalis
> T.denticola
> T.forsythia

Green / orange complex = periodontal and non periodontal infections

Yellow / purple complex = early colonizers

For perio disease to happen you need:

1- Susceptible host
2- Pathogen
3- Absence of beneficial bacteria

Q: **how can you determine that a certain bacteria is pathogenic?**

1- It has to be present or increased in numbers in site that exhibit disease and absent or reduced in number in sites that are healthy
2- Must provoke a host immune response [Antibodies]
3- Can cause disease in experimental animals
4- Has virulence factors that cause destruction of perio tissue

Dental deposits

- **Dental plaque =** yellowish microbial biofilm that adheres strongly to tooth and prosthesis surfaces
- **Acquired pellicle =** an Acellular layer layer made from salivary glycoproteins forms on the tooth surface even after being professionally cleaned

Importance of the acquired pellicle:

1- Lubrication → enhance speech and mastication
2- Regulation of minerals
3- Protection against demineralization
4- Host defense and antimicrobial function

Biofilm = group of microbial cells inside a matrix of extracellular polysaccharides.

- Biofilm contains organic components [poly saccharides, lipids, proteins] and in organic components [minerals]

Source of inorganic minerals for :

Supragingival plaque → saliva

subgingival plaque → gingival crevicular fluid

Q**: how does plaque form?** Salivary glycoproteins form the acquired pellicle on tooth surface→ early bacterial adhesion and attachment [The early colonizers bind to the acquired pellicle through certain receptors on the pellicle and then become themselves attachment sites for other bacteria] → bacteria already attached will multiply + allow other bacteria to attach → bacterial colonies form → cteria metabolize sucrose and form extracellular polyscharrides → plaque biofilm forms

The early colonizers [mostly streptococci + obligate aerobes + facultative anaerobes] will:

1- Provide binding sites for other bacteria
2- Modify the oral environment which helps the survival of other bacteria [ex: primary colonizers will remove oxygen → create an environment suitable for obligate anaerobes to survive]

- Strep sanguis [early colonizer] → binds to the pellicle by fibrils
- Actinomyces [early colonizer] → binds to the pellicle by fimbriae

Coaggregation: when two types of bacteria join together and form a complex structure [coaggregate] – binding between early and secondary colonizers

Ex: corncob formation – streptococci adhere to filaments of actinomyces species
Test tube brush formation – rods adhere to filamentous bacteria

When supragingival plaque becomes sub gingival plaque → bacteria change from gram +ve to gram -ve

Biofilm properties:

1- Bacteria arranged in microcolonies of diff environments
2- Bacteria in the biofilm cooperate together
3- Microcolonies are surrounded by extracellular poly scharrides matrix that has fluid channels for transport of nutrient and wastes
4- Biofilm is resistant to antibiotics

Mature plaque has mostly anaerobic bacteria because:

1- Early colonizers use the oxygen
2- Plaque thickness increases → less oxygen can diffuse to the inner species

Qourum sensing: how the bacteria microcolonies communication with each other in the dental biofilm

Supra gingival plaque	Sub gingival plaque
Found at or above the gingival margin If it contacts the gingival margin → marginal plaque	Found below the gingival margin Attached plaque - A. Tooth associated B. Tissue associated Unattached plaque – Subgingival microbiota is different than supragingival microbiota because: 1- CGF provide sub gingival plaque with nutrients 2- Anaerobic environment

- Marginal plaque → gingivitis
- Subgingival plaque → periodontitis
- Supra gingival plaque and tooth associated sub gingival plaque → root caries + calculus formation

- Plaque needs at least 4 days to be detected clinically
- Bacterial growth in older plaque is slower than newly formed plaque
- plaque accumulation is more next to inflamed gingival margins [due to increase in GCF]
- age does not influence plaque accumulation but developed plaque in older patients causes more severe gingival inflammation
- chewing fibrous food does not remove plaque

Factors affecting plaque accumulation:

1- **Tooth topography [**Plaque starts to accumulate along the gingival margin then proceeds coronally or from cracks, pit and grooves and then spread]
2- **Surface roughness** [rough areas and more plaque retentive]
3- **Individual variation [** some people are heavy plaque formers other are light plaque formers]
4- **Variation within the dentition [**more in the lower jaw, more in the molars , more in buccal compared to lingual , more in interdental compared to buccal surfaces]
5- **Smoking**
6- **Tongue brushing**
7- **Antimicrobial factors present in saliva**

Plaque hypothesis:

1- Non specific plaque hypothesis: plaque quantity not quality is related to the severity of the disease , so treatment is done by reducing plaque and OH measures
2- Specific plaque hypothesis : plaque quality [microbial composition] make it's pathogenic and is related to disease severity

3- **Ecologic plaque hypothesis:** both quality and quantity [microbial composition] is related to disease severity- suggests that periodontal disease is an opportunistic infection caused by changes in the balance between microflora and host hemostasis

Plaque disclosing agents:

1- **To calculate plaque index**
2- **Visual aid for the pts to motivate them to improve OH**
3- **Monitor effectiveness of plaque control**

Disclosing agent	Notes
Iodine	Stains plaque brown / black Unacceptable taste and can cause allergic reactions
Erythrosine	Stains plaque and gingiva pink Most widely used [what we use in clinics]
Two tone solution	Mature plaque → stains blue new plaque → stains red Does not stain gingiva
Fluorescein dye	Fluorescein based solution , invisible under normal light – requires special light Stains plaque → greenish yellow Does not stain gingiva or restorations Dye is not visible in normal light Has good contrast compared to the gingiva ** choose this one if you want to use a computer system for plaque quantification or for research
Tri plaque ID gel	New plaque → stains red Old plaque → stains purple Acid producing plaque → stains blue 

Q: what are the requirements of an ideal disclosing agent?

1- Acceptable taste
2- Has a color than can be easily distinguished from adjacent tissue
3- Does not wash off immediately
4- Should not cause irritation to the mucosa

Calculus : mineralized plaque has organic and inorganic components.

- Organic: desquamated epithelial cells, proteins, polyscharrides + micro organisms
- Inorganic: minerals [mostly calcium]

Supragingival calculus	Subgingival calculus
Above gingival margin White / yellowish white Hard claylike consistency Mostly: • Buccal surfaces of max molars [close to the parotid duct opening] • Lingual surfaces of lower anterior [close to the opening of submand and sublingual ducts] Source of mineralization = saliva	Below gingival margin Dark brown / greenish black Hard and dense • Has same HA content as supra gingival calculus • Higher magnesium • Less brushite • Ratio of calcium to phosphate is higher • Sodium content increases with the depth of periodontal pockets Source of mineralization = GCF

When the gingival margin receeds → it will expose subgingival calculus making it supragingival calculus

Supragingival calculus = supra gingival calculus + previous sub gingival calculus

Plaque needs around 12 days to be 90% mineralized

Q: how does calculus attach to the tooth surface?

1- Attaches to the pellicle on cementum [easily removed because there is no mechanical interlocking]
2- Attaches to enamel
3- Mechanical interlocking onto surface irregularities [hard to remove]
4- Undersurface of Calculus slowly adapts to the cementum and penetrates it

Theories of calculus mineralization:

1- Calcium and phosphate ions saturation increases and eventually precipitates in the plaque
2- Seeding agents cause small foci of calcification that later enlarge and join together

Q: why should calculus be removed? calculus is always covered with a layer of plaque that remains in close proximity to the gingiva

Gingivitis and plaque accumulation → strong correlation

Sub gingival calculus is a result of pockets not the opposite way – plaque accumulates → pocket formation → pocket is a perfect place for bacterial and plaque accumulation → plaque gets mineralized → sub gingival calculus

Q: **How is calculus detected ?** supragingival calculus is detected visually, subgingival calculus can be detected by explorer and by using air syringe to deflect the gingiva and view the calculus – heavy interproximal calculus can be detected by radiographs

Materia alba: white cheese like accumulation of loosely attached microoragnisms, desquamated epithelial cells , salivary proteins and lipids , few food particles – clearly visible no need for disclosing agent

- Materia alba → removed by water spray
- Plaque → removed by tooth brushing
- Calculus → removed by scaling / root planning

Mechanical plaque removal

Importance of plaque control – plaque must be removed to reduce inflammation, bleeding , bad odor and caries.

There is no relationship between design of the tooth brush and it's ability to reduce inflammation and bleeding.

Soft nylon brush:

1- is more effective in cleaning the cervical area
2- less traumatic to the gingival tissues
3- Can be directed into interproximal regions
4- Less chance of causing gingival recession and abrasion
5- Perfect for areas of gingivitis, necrotizing gingivitis or after perio surgery

> Tooth brushes should be replaced every 2-3 months [before filaments fray]
> Brushes should be kept in open air – apart from contacting other brushes

Powered tooth brushes for:

1- Children
2- Mental / physical disability
3- Pts with fixed ortho appliance
4- Hospitalized pts who need their teeth to be cleaned by care givers

- Targeted hygiene = focus on interproximal and cervical areas while brushing

Tongue cleaning – using tongue scraper

Interproximal cleaning:

1- Flossing : superfloss under bridges and in large diastemas

- Imp- floss should be inserted in an oblique manner [inserting it horizontally increases the risk of damaging the interdental papilla] – insert the floss slowly and don't snap through the contact area – the floss should curve around the tooth in a C shape
- For pts with poor manual dexterity or caregivers → hold floss in a floss holder

2- Tooth picks: used to run along the gingival margin and into the interproximal areas

3- Interdental brushes : also used under bridges - in furcation areas and distal surface of last molars

- diameter of the brush should be larger than the interdental space

Brushing technique

Brushing technique	Technique	Indication
Bass	Bristles are at 45 ° to the long axis of the tooth –bristles inside the sulcus Vibrate back and forth with short strokes Pressure should be firm enough to blanch the gingiva Modified bass : after the vibratory motion is completed in the sulcus sweep the bristles toward the incisal and occlusal surfaces. Limitation: 45° is hard to visualize – requires manual dexterity Pt might do it vigorously → damage the gingival margin 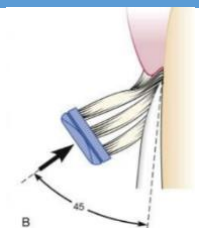	Most effective in cleaning the sulcus , cervical 3rd and GM Suitable for everyone but mostly taught for pts with periodontal disease
Rolling stroke	Direct filaments apically – place side of the brush on attached gingiva [plastic portion on the occlusal plane level] – press to flex the filaments – roll the brush towards occlusal / incisal surfaces while rotating the wrist Limitation: brushing too high can lacerate alveolar mucosa	Children with healthy gingiva In combination with bass, charters or stillman's
Modified stillman	Direct filaments apically – place side of the brush on attached gingiva – press to flex the filaments – direct the filaments at 45 with the long axis – rotary motion with light pressure [vibration] – continue vibrating and rolling towards incisal / occlusal surface 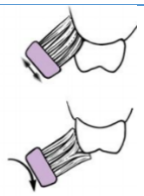	For pts with gingival recession Massages the gingiva
Charter's	Direct filaments 45° towards the occlusal plane at the gingival margin – forces the filaments interproximally and do rotary movements  Limitations: brush ends do not engage the sulcus + requires manual dexterity	Efficiently cleans interdentally Pts with ortho or fixed prostho Immediately after perio surgery

For all methods → **On occlusal surfaces** – short back and forth strokes with light pressure so the bristles clean the fissures and grooves effectively- excessive pressure will curve the filaments and they wont clean the pits and fissures. Make sure to clean the palatal and lingual surface

Chemical plaque control

Chemical plaque control using agents that:

1- minimize plaque accumulation
2- disturb plaque making it's removal easier
3- work directly against specific micro organisms causing caries / gingivitis
   - triclosan → reduces biofilm and gingivitis
   - 5% potassium nitrate → reduces sensitivity
   - Pyrophosphate salts → reduce calculus formation
   - Foaming of toothpaste is caused by : **sodium lauryl sulfate**
   - Alcohol in mouthwashes can interact with some medications , it also causes drying of the tissues → not used in pts with xerostomia
   - Substantivity = persistence of the effect of a topically applied medication
   - Gold standard in mouthwashes is second generation – they have the highest substantivity [CHX]

Commonly used mouthwashes:

1- Chlorohexidine: gold standard anti plaque / anti gingivitis

- Antimicrobial and anti gingivitis agent
- Bactericidal and bacteriostatic [depending on concentration]
- Causes bacterial cell lysis
- Binds to the pellicle + salivary proteins and prevents biofilm formation + binds to hard and soft tissues and then is slowly released from those sites [that's why it has high substantivity]
- Substantivity = 8-12 hours
- Available as : varnish, gel , mouthwash

Recommended uses of CHX:

1- Before SRP to decrease bacterial load
2- High caries risk pts
3- Pts with gingivitis / periodontitis / after perio surgery
4- Immunocompromised pts

Use : rinse with 10 ml for 1 minute twice daily for maximum of 2 weeks – rinse 30-45 mins after tooth brushing because sodium lauryl sulfate In tooth paste deactivates CHX

Adverse effects of CHX:

- Oral mucosa desquamation
- Brown staining of teeth and tongue and restorations
- Temporary taste impairement
- Increased supragingival calculus formation

2- Essential oil mouthrinses: ex-listerine

Reduces biofilm and gingivits

Recommended for:

1- Pts who cannot perform adequate OH with brushing and flossing
2- Use periodically to improve oral hygiene
3- Before scaling to decrease bacterial load

Adverse effects:

- Burning sensation
- Bitter taste
- Staining

4- Triclosan: Reduces biofilm and BOP

5- Quaternary ammonium compounds

- Reduce bio film but little improvement for gingivitis
- Same adverse effects as CHX

6- Oxygenating agents : 1.5 % hydrogen peroxide

- Cause bacterial cell lysis
- Short term use in cases of pericorinitis and NUG
- **Prolonged use of 3 % hydrogen peroxide → gingival irritation + delayed healing**

7- Biotene : [enzymes]

- For people with dry mouths
- Contain lysosome / lactoperoxidase

**** increasing tooth brushing to 3-4 times daily → not more effective in improving periodontal condition**

Ideal plaque control = mechanical + chemical means + remove plaque retention areas [overhangs, over contoured restorations , rough restorations , construct better fitting dentures, ortho tx to re align mispositioned teeth etc]

periodontal instruments

- Hollow handles conduct Vibrations better → better tactile sensitivity
- Angles in the shank are made to allow access to certain areas
- Lower shank = part of the shank closer to the working end
- Perio instruments are held by modified pen grasp

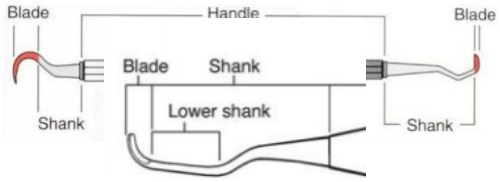

3 most used probes =

- Michigan O probe [marking 4 and 6 are missing]
- UNC 15 probe [15 mm markings]
- WHO probe [has 0.5 mm ball point]

For furcation involvement – Naber's probe

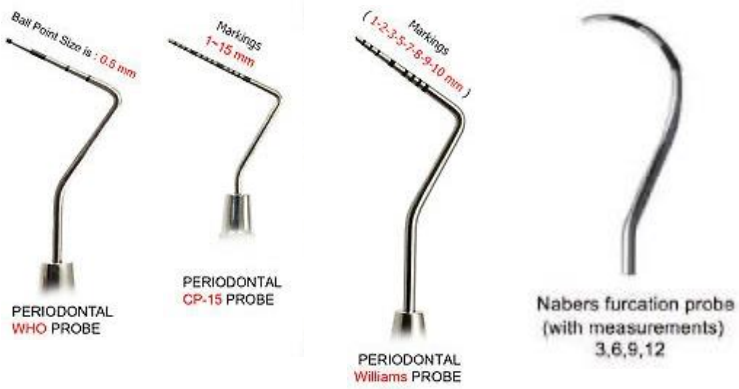

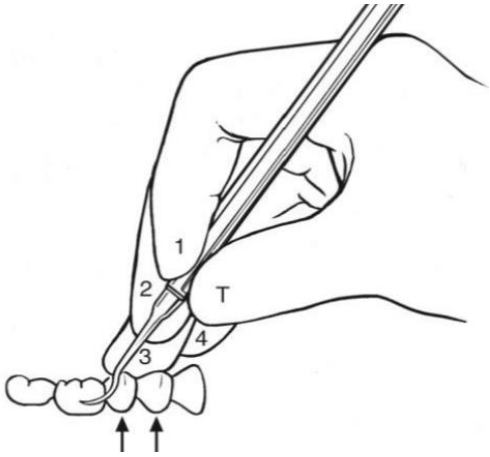

Sickle scalers → for supragingival calculus – pointed end

Scalers [sharp pointed tip – remove supragingival calculus]	
Sickle	**Straight [jaquette]**
2 cutting edges Curved blade **Blade = triangular cross section** **Face of the blade is adapted to the tooth at 70° angle** **Use: remove supragingival calculus** 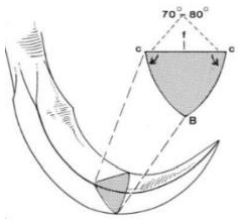	2 cutting edges **Straight blade** Blade = triangular cross section Face of the blade is adapted to the tooth at 70° angle Use: remove supragingival calculus 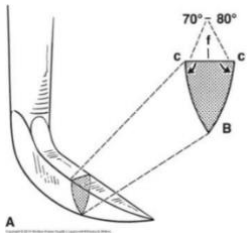

Mcall [universal] scaler :

- Can be used anteriorly and posteriorly [but mainly posteriorly]
- 2 cutting edges at 90° to tooth surface

Sickle scaler [anteriorly]	Mcall universal scaler
Handle parallel to long axis of the tooth	Lower shank parallel to long axis of the tooth

File scaler :

- Multiple blades at 90° to the shank
- Remove large calculus if power scalers are contraindicated
- Fractures calculus before the use of curettes – must always be followed by curettes to smoothen the surface

Chisel scaler :

- Single straight cutting blade that is continuous with a curved shank - Blade beveled at 45°
- Removes interproximal calculus on anterior teeth – dislodge heavy calculus when there is a continuous bridge of calculus over anterior teeth
- The only scaler used in a push stroke

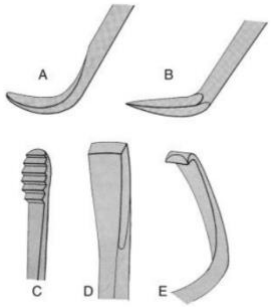

The five basic scaling instruments.
A, Curette; **B,** sickle; **C,** file; **D,** chisel; **E,** hoe

Hoe scaler :

- Single straight cutting blade that is at 99° to the shank - Blade beveled at 45°
- Remove large pieces of supragingival calculus

For effective instrumentation and calculus removal → adequate access and visibility + meiantian a clean field + use sharp instruments

While scaling the wrist should be in neutral position, excessive wrist bending → cramping of the median nerve in the carpal tunnel → carpal tunnel syndrome

Finger rests: prevents accidental slippage of the instrument and ST damage + allows optimal blade adaptation [4th finger is used]

Intraoral :

- Conventional – rest adjacent to the area you are working on
- Cross arch – on the opposite side of the same arch
- Opposite arch – on the opposing arch
- Finger on finger – on the index or thumb of the non working hand

Extraoral finger rests:

Palm up : on the right side of the face

Palm down : on the left side of the face

Q: what are the factors for instrument activation?

1- **Adaptation :** the way the working end is adapted onto the tooth surface – working end should a follow the contour of the tooth surface – the terminal 3rd of the blade must be in contact with the tooth surf at all times
2- **Angulation :** the angle between the blade and the tooth surface
- **During subgingival insertion → 0 °**
- **During scaling and root planning 45 -90 °**

3- **Lateral pressure :** when removing calculus → firm pressure then it should gradually decrease Light pressure for root planning
4- **Stroke:** exploratory, scaling, root planning

Curettes → for subgingival scaling and root planning – rounded end

Universal curettes	**Area specific curettes – Gracey curettes**
Blade is at 90° to the lower shank 2 cutting edges Blade = semi circle cross section Blade curved in one direction – blade goes upward	70° offset blade One cutting edge – the one with a larger outer curve Blade = semi circle in cross section Blade curved in 2 directions [upward and to the side] **Lower shank parallel to the tooth**
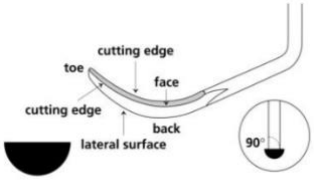 **Universal Curette**	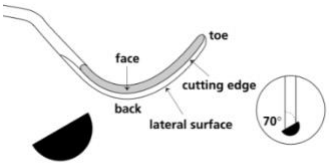 **Gracey Curette**

Gracey curette #	**Use**
1-2 & 3-4	Anterior teeth – all surfaces
5-6	Anterior and premolars
7-8 & 9-10	Facial and lingual of posterior teeth
11-12	Mesial of posterior
13-14	Distal of posterior
15-16	Modification of 11-12 [blade of 11-12 but shank of 13-14]
17-18	Modification of 13-14 [terminal shank = elongated by 3 mm + blade is 1 mm shorter]

Curette modifications

- **After 5 curettes: used for pockets more than 5 mm deep**
  - all are modified except for 9-10
  - Terminal shank= elongated by 3 mm
- **Mini 5 curettes :** modification of after 5 - **Blade = ½ of the length of after 5 blade**
- **Micro – mini 5 curettes: blade = 20% thinner than mini five curettes**
- **Langer and mini langer curettes:** shank of 5-6 & 11-12 & 13-14 but with 90° blade

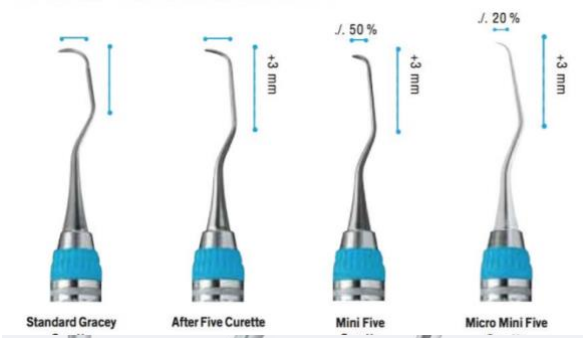

Schwartz periotrievers : have magnetized tips to retrieve any broken instruments from the pocket

Contra angled → for furcation long → for pockets

To scale around implants → use plastic or titanium curettes

Power scalers

- Have different tips for supragingival and subgingival scaling

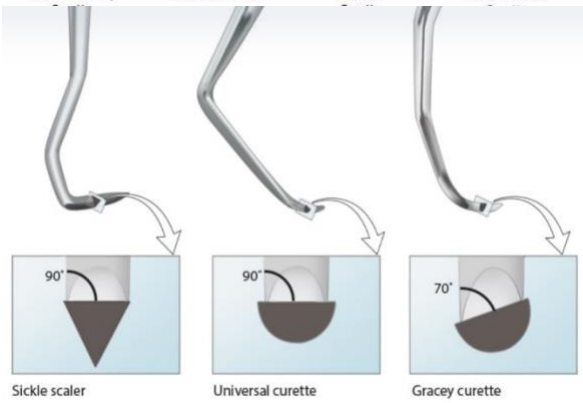

Water in power scalers causes:

1- **Acoustic streaming** = fluid flow caused by ultrasound waves → forces that remove calculus and plaque + flush the pocket
2- **Acoustic turbulence** = movement of the tip causes the coolant to accelerate until it forms cavitations
3- **Cavitations** = bubble activity in a liquid that beak and release energy to remove plaque
4- **<u>Provides continuous flushing of the pocket from debris</u>**

You adapt the lateral surfaces on the tooth and the tip [the highest energy]-can be adapted on the calculus/ deposit

US tips have 2 lines to indicate wear:

- Blue line – when the tip reaches here – the efficiency drops by 25%
- Red line – wen the tip reaches here – the efficiency drops by 50% [throw it out]
- Beveled tips → calculus removal
- Round tips → plaque debridement

Power scalers can be :

Sonic	Ultrasonic
air pressure converted to high frequency sound waves attached to the dental unit noisy tip rotates in a circular motion less powerful than ultrasonic	**electrical energy converted to high frequency sound waves** **Piezoelectric scalers:** less sound tip moves in linear way – lateral surfaces are more active **most expensive** ** it does not heat the water → pts might complain of cold sensitivity – some might have a separate water warmer **Magneto strictive :** generates most heat tip moves in elliptical manner – all tip surfaces are active

- **High frequency sound waves cause the tip to vibrate → breaks off the calculus**
- **In power scalers you can adjust the amplitude but not the frequency**

Advantages of power scalers	Disadvantages of power scalers
1- Increased efficiency 2- Less chance of wrist strain injuries 3- Water will provide continuous irrigation 4- Less lateral pressure required **5-** Medications like CHX can be attached to the scaler and delivered directly to the pocket	1- Can cause discomfort for the pt [sound and water] 2- More precautions and limitations than hand scalers 3- Less tactile sensitivity 4- Reduced visibility 5- Aerosol production [which can contain pathogen harmful to the practitioner] ** pt can rinse with CHX for 1 min before scaling to reduce bacterial load in aerosol. + use high volume suction to limit aerosol

Indications of power scalers	Contraindications for power scalers
1- Supragingival / subgingival / furcation calculus removal 2- Removing ortho cement 3- Removing overhanging margins of restorations 4- Initial debridement of NUG cases **5-** Remove gross debris before perio surgery	**Pt health/ operator :** 1- Pts with cardiac pacemakers – scalers will cause electromagnetic interference 2- Pts with swallowing difficulties or severe gag reflex 3- Asthma pts [aerosol and infectious materials as easily be aspirated into the lung] 4- Immunocompromised pts [diabteics, pts on chemotherapy and corticosteroids – they are at higher risk of infections from the aerosol] 5- Pt has diseases that can be transmitted by aerosol [hepatitis, TB , resp infections] **Tooth :** 1- Demineralized surfaces / exposed dentine → can become more sensitive 2- Primary teeth → heat from US tip can lead to pulp damage

Defense mechanism of the gingiva

Gingival defense to disease

1. Saliva
2. Physical barrier by gingival epithelial cells
3. JE high turn over rate
4. JE as semi permeable membrane- allowing immunoglobins to reach the sulcus
5. JE releases cytokines to recruit PMNs
6. GCF [produced by sulcular epithelium] – contains leukocytes, electrolytes , proteins
7. Poly morpho nuclear neutrophils – PMNs
8. Non specific antibodies

Factors that affect GCF:

1- Circadian rhythm = there is increase in GCF from 6am to 10 pm then it decreases
2- Sex hormones = female sex hormones increase GCF
3- Mechanical stimulation = chewing and gingival brushing increases GCF
4- Smoking = causes immediate increase in GCF
5- Periodontal therapy = GCF increases after perio surgery

Q: how can you collect GCF?

1- Use absorbing paper strips
2- Twisted threads
3- Micropipettes
4- Intracrevicular washing

- Glucose concentration in GCF is 3-4 times greater than that in serum but total protein content of GCF is less than that of serum.
- No correlation between concentration of protein in GCF and severity of gingivitis, pocket depth or bone loss
- GCF = inflammatory exudate and amount increases with inflammation and may be proportional to severity of inflammation
- Antibody in saliva = sIgA and IgG and IgM

Function	Salivary Components	Probable Mechanism
Lubrication	Glycoproteins, mucoids	Coating similar to gastric mucin
Physical protection	Glycoproteins, mucoids	Coating similar to gastric mucin
Cleansing	Physical flow	Clearance of debris and bacteria
Buffering	Bicarbonate and phosphate	Antacids
Tooth integrity Maintenance	Minerals	Maturation, remineralization
	Glycoportein pellicle	Mechanical protection
Anibacterial Action	IgA	Control of bacterial colonization
	lysozyme	Breaks bacterial cell walls
	lactoperoxidase	Oxidation of susceptible bacteria

antibody in GCF = IgG

Gingival disease pathogenesis

Gingivitis: inflammation of the gingiva might be plaque induced or non plaque induced.

Plaque induced gingivitis – micro organisms in plaque are in close contact to gingival tissue and release [endotoxins, collagenase and proteases] → epithelial and CT destruction

Gingivitis Stage	Clinical appearance
Initial	Sub clinical gingivitis No clinical signs ** mostly PMNS cells
Early	Erythema [due to proliferation of blood vessels Bleeding on probing Increase in GCF ** mostly lymphocytes
Established	Blood vessels are engorged and congested – anoxemia → bluish hue on the red gingiva Breakdown of hemoglobin → deepening of the color of the inflamed gingiva Established lesions may progress or may remain stable ** mostly plasma cells
Advanced [Periodontitis]	CAL and bone changes

> **Diffuse gingivitis:** involves GM + attached gingiva + interdental papilla
> **Earliest sign of gingivitis** → BOP [appears before any color changes in gingiva]
> **Gingivitis in children** → Less clinical sign [even with large amounts of plaque]

- **Probe in healthy tissue** → remains within JE because it is resisted by the dense collagen under the epithelium → no BOP
- **Probe in inflamed gingival tissue** → pushes through the JE and penetrates underlying inflamed CT → resisted by the collagen fibers under the inflamed region → BOP

Gingivitis clinical signs :

1- BOP ***
2- Erythema [proliferation of blood vessels]
3- Edema and swelling
4- Loss of stippling due to CT destruction

Acute gingival lesions

- Develop quickly [within hours or days]
- associated with pain/ discomfort + swelling +/- fever → require immediate attention

ACUTE NECTROTIZING GINGIVITIS [NUG] – ALSO CALLED VINCENT'S DISEASE, TRENCH MOUTH , FUSO SPIROCHETAL GINGIVITIS

INFLAMMATORY DESTRUCTION **OF THE GINGIVA ASSOCIATED WITH IMPAIRED HOST RESPONSE – MOSTLY STRESS [IT IS NOT FOUND IN PTS WITH GOOD IMMUNITY] -** NOT CONTAGIOUS OR COMMUNICABLE BUT OCCURS IN GROUPS IN AN EPIDEMIC PATTERN	
HISTORY	history of : A. acute respiratory tract infection / debilitating disease B. sudden change in living habits C. continuous work without rest D. poor nutrition / smoking / stress ** all can lower the immune system and make the host more susceptible
CLINICAL APPEARANCE	1. Punched out crater like depressions that start from the tip of the interdental papilla and extends to the marginal gingiva [might extend to the attached gingiva or alveolar mucosa] 2. Surface of the crater is covered by greyish pseudomembranous slough surrounded by linear erythema 3. Spontaneous bleeding 4. Fetid odor 5. If it is associated with bone resorption → necrotizing ulcerative periodontitis [usually in pts with HIV] ** NUG does not lead to pocket formation ** usually occurs superimposed on gingivitis or periodontitis but can occur in healthy mouths  
ORAL SYMPTOMS	1- Constant Radiating pain that becomes worse when chewing or eat spicy / hot foods 2- Lesions are sensitive to touch 3- Metallic taste 4- Excessive ''Pasty'' saliva
EXTRA ORAL SYMPTOMS	1- Local lymphadynopathy 2- Mild fever 3- In severe cases → extrely high fever + increased pulse + loss of apetite 4- In rare cases → Noma [gangerenous stomatitis]
DIAGNOSIS	Based on clinical apperance – no need for bacterial smear testing [because it is not very different from bac in gingivitis or periodontitis] Bacterial tetsing can be done if you suspect oral thrush [candida] , diptheria etc ** leisons usually have fusiform bacteria and spirochetes
DIFFERENTIAL DIAGNOSIS	1- Desquamative gingivitis 2- Primary herpetic gingivostomatitis 3- Chronic periodontal disease 4- Streptococcal gingivo stomatitis

TREATMENT

First visit :

1- Ask the pt when this problem started and if it is recurrent or not + identify the cause of suprressed immunity [stress, life changes , disease, medications etc]
2- Measure temperature and palpate lymphnodes
3- Appply topical anesthesia to involved areas + isolate areas with cotton rolls
4- Swab the areas with a cotton pellet to rmeove pseudomembraneous tissues → clean the area with warm water and then remove supragingival calculus [use US scalers] – less painful + provide flushing of the tissues

** subgingival scaling should not be done at this stage because it can further spread the disease to deeper tissue

**Pt should rinse every 2 hours with a glass of equal mix of warm water and 3% hydrogen peroxide and / or twice daily 0.12% CHX

**Any other tx that is not urgent should be postponed untill the pt is symptom free for 4 weeks

**If the pt has any systemtic complications [lymphadynopathy, fever, anorexia , malaise etc] → ABX

- Amoxicillin 500 mg every 6 hours for 10 days
- Penicillin allergic pt →
  500 mg erythromycin every 6 hours
  or 500 mg metranidazole twice daily for 7 days

**ask the pt to avoid smoking – alcohol- physical activity or excessive exposure to sunlight

** maintain adequate fluid intake

** they can take NSAIDs/ ibuprofen for pain

Second visit : [1-2 days after]

Evaluate pt condition and gingival response [there should be improvement + less pain]

you can do scaling

ask the pt to continue your previous instructions

Third visit : [5 days after the second visit]

Pt should be symptom free

Stop hydrogen peroxide but continue CHX for 2-3 weeks

You can do SRP

Treat all over pockets, pericoronitis and gingivits then re evaluate after 1 month [to see the need for perio surgery to imporve esthetics]

Recurrent cases/ non responsive cases :

1- **Re evaluate your DD**
2- **Consider the effect of systematic disease**
3- **Consider inadequate tx or pt compliance**

Streptococcal gingivostomatitis [rare]

- Diffuse erythema of the gingiva + other areas of the mucosa
- Bacterial smears show many streptococcal bacteria

GINGIVAL ABSCESS

CAUSE	Bacteria carried deep into the tissue by a forgein object [tooth brush bristle, piece of apple core, lobster shell etc] and it is forcefully inbedded in the tissue
CLINICAL APPEARANCE	- Localized painful rapidly expanding lesion with sudden onset - Limited to gingival margin and interdental papilla - In early stages → red swelling with smooth shiny surface but after 24- 48 hours lesion becomes fluctuant and puss can be expressed [lesion might rupture spontaneously] - Adjacent teeth are sensitive to percussion 
TREATMENT	1. Remove the cause 2. LA 3. SRP to establish drainage 4. In severe cases the fluctuant area scan be incised with a #15 blade to establish drainage + irrigated with warm water and then cover with moist gauze under pressure → pt is instructed to rinse with warm salt water every 2 hours for the rest of the day 5. Re asses after 24 hours – you can complete SRP if not done before if the lesion is still large → surgical access

RECURRENT APTHOUS STOMATITIS [RAS]

CAUSE	- Unkown , multiple theories
CLINICAL APPEARANCE	- 0.5 – 1 cm well defined ovoid or round shallow ulcers with yellowish / grey central surrounded by erythematous halo that heal in 7-10 days without scarring - Larger 1-3 cm irregular ulcers take weeks to heal and they scar ** ulcers are very similar to PHGS but there is no systemtic symptoms or diffuse gingival erythema ** history of painful ulcerations → RAS 

- RAS→ ulcers occur on non keratinized mucosa
- PHGS → ulcers occur on keratinized tissue [gingiva + palate]

PERICORONITIS

INFLAMMATION OF THE GINGIVAL TISSUE COVERING A CROWN OF A PARTIAL ERUPTED TOOTH [USUALLY MANDIBULAR 3RD MOLAR]	
CLINICAL APPEARANCE	- Red , swollen , suppurative lesion that is very tender to touch - Pain radiates to ear , throat, floor of the mouth

	- Foul taste and inability to close the mouth [trismus] - Facial swelling at the angle of the mandible / cheek - Fever + malaise **The space between the operculum and the tooth causes food accumulation + bacterial growth **Acute exacerbation occurs due to trauma from occlusion or forgein body entrapment **Complications:** 1- Might become a peri coronal abscess 2- Might spread posteriorly / medially to the floor of the mouth making it hard to swallow 3- Can become incubation zone for NUG ** might lead to peritonsillar abscess and cellulitis → I & D if there is an abscess
TREATMENT	sh the area under the operculum with saline/ warm water to remove debris / exudate vate the flap gently and swab the area with an antiseptic eck occlusion of opposing tooth – it might need adjustment to reduce pain ** ABX is given in cases of systemic involvement / bacterial infiltration into the tissue

**** asymptomatic peri coronal flaps should be removed as a preventative measure**

PRIMARY HERPETIC GINGIVOSTOMATITIS [PHGS]

CAUSE	**Herpes simplex virus [HSV-1]** **As part of the primary infection the virus ascend to the neuronal ganglia that innervates the site and remains dormant.** **** contagious disease – but most adults gain immunity as a result of subclinical disease during childhood**
HISTORY	**Virus is reactivated due to : sunlight, trauma, fever, stress , dental tx causing → secondary herpetic infection [herpes labialis , herpetic stomatitis , genital and ocular herpes]**
CLINICAL APPEARANCE	- **Mostly in infants and children below 6 YO** - **In the early stage → discrete spherical grey vesicles [on soft palate, tongue, gingiva, mucosa]** **→ that rupture after 24 hours leaving painful ulcers [depressed yellowish, greyish- white center with raised red margins]** **** sometimes it occurs without vesicles and just as diffuse erythematous, shiny edematous gingival enlargements** **** disease course = 7-10 days** **** vesicles heal without scarring** **** herpetic whitlow is the infection of the clinician's finger due to herpes** **** secondary herpetic lesions can occur on the gingiva / mucosa / palate after reactivation due to dental TX they usually occur 2-4 days after tx**
ORAL SYMPTOMS	**1- Soreness that interfers with eating and drinking** **2- Ulcers are sensitive to touch, heat and fruit juices** **3- In infants → irratibility and refusal to eat**
EXTRA ORAL SIGNS	**1- Fever reaching 40** **2- Cervical lymphadenitis** **3- Malaise**
DIAGNOSIS	**Based on history + clinical appearance – culture can be taken from the lesion for bacterial testing**

DIFFERENTIAL DIAGNOSIS	**1- NUG** **2- Desqumative gingivitis** **3- Apthous ulcers** **4- Bullous lichen planus**
TREATMENT	**** early diagnosis and immediate antiviral therapy** **If diagnosis is made within 3 days of onset → 15 mg/ kg of body weight Acyclovir suspension 5 times daily for 7 days + NSAID** **If diagnosis is made after 3 days of onset + pt is immunocompetent → don't give acyclovir** **** pts can use topical anesthetics to reduce pain while eating** **** postpone all perio tx until symptoms subside** **** all pts recieve pallative care → remove food debris + plaque** **** if condition does not resolve within 2 weeks → refer to a physician** **** warn the pt that this disease is contagious → all exposed individuals should take precautions**

Periodontal pathogenesis

Gingivitis → inflammation extending towards the PDL → causing CAL + bone resorption → periodontitis

> **There is a cause and effect relationship between plaque and gingivitis**
> **Periodontitis is ALWAYS preceded by gingivitis , but not all gingivitis progresses to periodontitis**

Q: how can the gingival inflammation spread causing CAL and bone loss?

Interproximally

1. Gingiva to bone
2. Bone to PDL
3. Gingiva to PDL

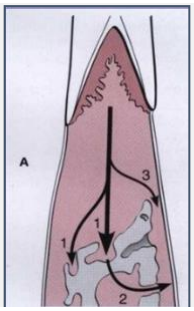

Buccaly and lingually

1. Gingiva to periosteum
2. Periosteum to bone
3. Gingiva to PDL

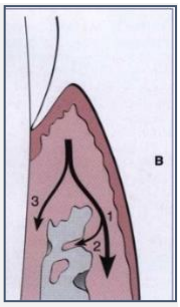

**** inflammation can enter the bone from more than one pathway and after entering the bone it can enter again the PDL**

Q: how does a pocket form? Lipopolyscharrides [LPS - bacterial endotoxin] activates PMNS to release collagenase/ MMPS and proteases → Collagen fibers apical to the JE are destroyed and the area becomes filled with inflammatory cells → JE migrates apically → pocket forms

At the same time LPS activate macrophages to release cytokines → RANKL activation → osteoclast formation → bone resorptions

Pockets are basically chronic inflammatory lesions that undergo cycles of activity and repair

Periodontitis clinical appearance

Periodontitis clinical appearance	Gingivitis clinical appearance

1- Gingival swelling and inflammation
2- Gingiva might be fibrotic as a result of long standing inflammation
3- Plaque & calculus accumulation
4- Pockets or recession
5- BOP
6- CAL ***
7- Bone loss ***
8- Furcation involvement
9- Tooth mobility ***

1. Gingival erythema
2. Loss of stippling
3. Gingival swelling
4. BOP

Bone loss in periodontitis

Horizontal	Vertical
bone loss in uniform on the majority of tooth surfaces causes supra bony pocket formation	bone loss on one surface is greater than the adjacent surface causes infrabony pocket formation

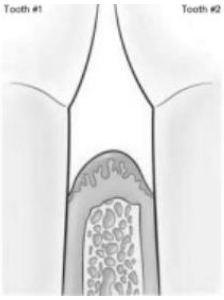

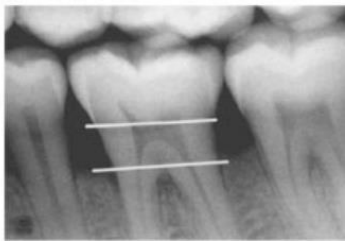
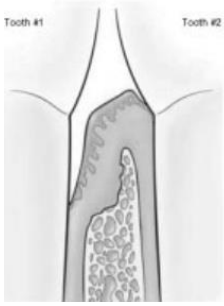

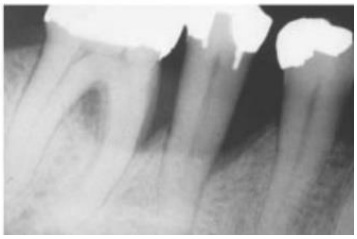

Periodontitis symptoms

1- Pts will first notice that they have periodontitis when their gums bleed during brushing / eating
2- Spacing between the teeth because of tooth migration
3- Mostly **NO PAIN** *** [that's why pt's refuse tx or recommendations]
4- Pain might be present in case of gingival recession and hypersensitivity
5- **Gingival itchiness** ***

** periodontitis can occur at any age and it is site specific – some areas in the mouth might have more rapid disease progression and CAL [due to localized factors that cause plaque accumulation like overhangs and sub gingival margins, furcations , malposed teeth etc]

** periodontitis is an age associated and not age related disease → not all eldery will develop periodontitis [specially if they maintain good OH]

Risk factors for periodontitis

- **Risk =** the probability that a person will develop a certain disease in a given period
- **Risk factors =** identified through longitudinal studies – factors when present increase the likely hood that a person develops a disease [smoking – diabetes- pathogenic bacteria – plaque and calculus]

> There is no relationship b/w OH and susceptibility to periodontitis- Plaque causes gingivitis but not periodontitis → teeth with severe CAL might not have any microbial deposits

Calculus which acts as a reservoir for plaque is a risk factor for periodontitis

** Areas that increase plaque accumulation and make it harder for the clinician to remove → increase disease susceptibility [developmental root grooves, enamel pearls , cervical enamel projections, root concavities , furcations, subgingival restoration margins, overhanging restorations]

3 types of bacteria have been associated with periodontitis:

1- Aggregatibacter actinomycetemcomitans (formerly Actinobacillus actinomycetemcomitans)-**AA**
2- Porphyromonas gingivalis
3- Tannerella forsythia (formerly Bacteroides forsythus)

RISK DETERMINANTS / BACKGROUND CHARACTERISTICS = RISK FACTORS THAT CANNOT BE MODIFIED

GENETIC FACTORS	This is why some people might develop periodontitis and other wont
AGE	Prevalence and severity of periodontitis increase with age CAL/ bone loss seen in older pts is a result of prolonged exposure to risk factors over time ** not all old pts will develop periodontitis [specially if they maintain good OH throughout their life] – age is NOT a risk factor for periodontitis
GENDER	Men have more CAL than women because they have worse OH and higher levels of plaque and calculus
SES	Lower SES → more gingivitis and poor OH is related to lack of awareness and infrequent dental visits
STRESS	

RISK INDICATORS = PROBABLE RISK FACTORS [IDENTIFIED THROUGH CROSS – SECTIONAL BUT NOT LONGITUDINAL STUDIES]

HIV / AIDS	**Conflicting data – some say HIV increases pocket formation and CAL other say there is no relationship** **HIV pts with good OH → no periodontitis**
OSTEOPOROSIS	**Conflicting data – some said osteoporosis causes more CAL other said no relationship**
INFREQUENT DENTAL VISITS	**Controversial – some said there is more severe periodontitis in pts that don't visit the dentist , other said no changes .**

RISK MARKERS / PREDICTORS = ASSOCIATED WITH INCREASED RISK TO DEVELOP THE DISEASE BUT DON'T CAUSE IT

HISTORY OF PREVIOUS PERIODONTITIS	**Pts with existing CAL → highest risk for future loss**
BOP	**BOP = best clinical indicator or gingivitis** **Lack of BOP is not an indicator of health** **BOP + CAL → predicts future CAL**

Risk assessment for periodontal risk → by clinician of computer based system [periodontal assessment tool – PAT collects data from 23 item to develop risk assessment and quantification of current disease]

**** CAL due to continuous tooth eruption to maintain occlusion is not considered periodontitis**

Periodontitis risk factors

1- Plaque and calculus ** [pts with good oral hygiene will not develop gingivitis that leads to periodontitis]

- **some cases of periodontitis might have no or very little plaque accumulation**
- **Not all cases of gingivitis will progress to periodontitis**

2- Immunocompromised pts
3- Smoking
4- Diabetes
5- Emotional stress

- it is unlikely that there is a clear genetic predisposition to periodontal disease
- Systematic diseases alone cannot cause periodontitis without presence of plaque
- <u>Plaque is necessary to cause periodontitis but it is not sufficient to cause it</u>
- Periodontitis occurs when Plaque is present + host immunity is compromised [by smoking , disease , stress etc..]

Smoking and periodontitis

Tobacco :

A. **gas phase** (carbon monoxide , formaldehyde and ammonia)
B. **solid phase** (nicotine –**tar** which **stains fingers and teeth yellowish brown**)

To asses smoking status we measure **cotinine** (metabolite of nicotine) because it has a long half life compared to nicotine.

- Normal cotinine saliva / plasma level = less than 2 ng/ml
- Smokers cotinine saliva/ plasma level = 300 ng/ml

1 pack year = Patient smokes 20 cigarettes per day for 1 year.

Tobacco smoke

- **1st hand smoke** = smoke inhaled by the smoker
- **2nd hand smoke** = smoke exhaled by the smoker (mainstream) or released by the cigarette (sidestream)
- **3rd hand smoke =** the smoke that remains in air after a cigarette is smoked

Passive smoking / environmental smoke / second hand smoke = the smoke inhaled by people surrounding a person who smokes.

- **Current smokers =** smoked 100 cigarettes or more in their lifetime and currently smoke
- **Former smokers** = smoked 100 cigarettes or more in their lifetime and currently don't smoke
- **Non- smokers =** smoked less than 100 cigarettes and currently don't smoke

Water pipe/ hooka smokers are X5 at risk of perio disease - Cigarette smokers are X4 at risk of perio disease

Effects of smoking on periodontal disease:

1- less clinical features of inflammation [gingivitis] & less BOP (smoking masks the inflammation)
2- deeper probing depths and greater number of deep pockets
3- More CAL and recession
4- More furcations involvement
5- More bone & tooth loss
6- Higher rate of perio destruction

Smokers have same rate of plaque accumulation as non – smokers but they have more colonization by perio pathogens

Q: why would a smoker have more periodontal destruction than a non – smoker even though the rate of plaque accumulation is the same?

1- Smokers have more colonization by periodontal pathogen [qualitative effect not quantitative]
2- Carbon monoxide will lower o2 tension in the pockets and favors the growth of anaerobic bacteria **even in shallow pockets** (**p.gingivalis , AA, p.intermedia**)

3- Smoking impairs the response of neutrophils but increases the release of destructive enzymes → faster disease progression
4- Smokers have high number of leukocytes in blood but few only go to the gingival crevice
5- Smokers have reduced PMN and macrophage function (recduced phagocytosis , chemotaxis)

Q: why do smokers have less BOP ? This is caused by the interaction of the chemicals and the heat from smoking

Smokers response to tx :

1- Less reponse to tx
2- Less reduction in pocket depth
3- Less attachment gain and bone fill
4- Less survival rate of implants
5- Increase furcation development after surgery , recession and membrane exposure after GTR
6- Increase pocket depth during maintenance
7- Increase in **BOP after they stop smoking**

** gingiva loses it's fibrotic appearance one year after stopping smoking.

Smoking cessation protocol : The 5 A's ***

- **Ask :** know their smoking status and tobacco use [when did you start smoking, how often do you smoke, how many cigarettes, did you try to quit before?]
- **Advise :** tell them the effect of smoking on their health and oral cavity + benefits of quitting
- **Asses:** patient readiness to quit smoking **[pt must say I want to quit NOT I NEED to quit]**
- **Assist:** use appropriate techniques to help the pt quit smoking [removes cigarettes , give brochures]
- **Arrange:** follow up with the pt [1-2 weeks after quitting]

You should ask the pt every visit about their interest in quitting smoking.

Q: what if the pt is not willing to quit smoking now?

<u>Use the 5 R's :</u>

1- **Relevance :** determine relevance of quitting to the pt
2- **Risk :** discuss risks of smoking with the pt
3- **Rewards:** discuss reward of quitting
4- **Roadblocks:** discuss possible roadblocks to quitting
5- **Repition:** repeat this discussion

Basic clinical periodontal appearance of a smoker : ***

1- No signs of gingival inflammation , gingiva appears a little bit fibrotic
2- No BOP **but they start to bleed more when they stop smoking**
3- Greater number of deep pockets and bone loss

Lowest to highest risk of periodontitis : non smokers – former smoker – smoker

- Smoking has a very strong association with NUG.
- Smoking is the only preventable risk factor for periodontitis.
- The periodontal cost of smoking is 27 years of disease progression [a 30 YO smoker will have the same periodontal status as a 57 YO]

Illicit drugs effect on periodontal health

Marijuana (cannabis)

- Cannibas use predisposes to depression later in life. [depression is more in women]

Oral effects:

1- Dry mouth
2- Sweet food cravings
3- Gingival hyperplasia
4- Fiery red patches on the gingiva
5- No studies showed perio risk
** most pts are also smokers + pts will also have lack of motivation and neglect their dentition

Methamphitamines : **CNS stimulant**

- Causes feelings of excitement, euphoria, feeling confident and energetic
- Taken orally , intranasally, smoked or injected
- Causes violent behaviour , mood disturbances and hallucinations [feeling of insects crawling onto skin]
- **Increased risk of parkinson's later in life.**

Oral effects:

1. Rampant caries [due to hypo salivation + lack of oral hygiene + high sugar consumption]
2. Bruxism

Cocaine :

- White odorless powder
- Numbing bitter taste
- Inhaled – injected – smoked or rubbed against the gingiva

Oral effects:

1. Rubbing it against the gingiva will cause ANUG like lesions
2. Perforation of the nasal septum or palate
3. Cervical caries [because glucose is a filler in cocaine]
4. **Severe localized bone destruction → cocaine periodontitis**

**** recent use of cocaine → cardiac complication in the dental clinic [specially if you used LA+ epinephrine or epinephrine impregnated cords]**

Heroin :

Oral effects:

1- xerostomia + caries + sweet cravings
2- associated with hep B and C

Ecstacy [street names : E, XTC, eccy]

- Similar effect to amphetamines

Oral effects:

1- Bruxism
2- Reduced salivary flow

3- Mucosal ulcerations – caused by the drug being held against the gingiva
**** pts using ecstasy have tolerance to LA**

Stress and periodontitis

Acute stress = few minutes or hours

Chronic stress = days and weeks

Stress alone will never cause any disease, pt's susceptibility to disease depends on pt's ability to cope with the stress.

- **Good coping strategies** = less stress effect on health
- **Poor coping strategies =** reliance on smoking and drinking , avoid the problem or pretend it is not there
- **Primary stress hormone = corticotropin releasing hormone**

Q: how can stress be related to periodontitis? **

Stress → causes increase **corticotropin releasing hormone [CRH]** from the **hypothalamus** → CRH causes **anterior pituitary** to release **corticotropin** → corticotropin causes the **adrenal cortex** to release **cortisol + glucocorticoids** into the blood → suppress immune response (suppresses neutrophil activity , reduce IGg and SIgA) + increase blood glucose and alter levels of growth factors → allows perio pathogens to cause tissue destruction.

Stress also causes behavioral change :
Direct behavior change – poor oral hygiene → plaque accumulation → periodontitis
Indirect behavior change – tobacco use, alcohol , bad nutrition → reduced immune response → periodontitis
Cortisol [stress hormone] can be detected in blood, saliva and GCF

Diabetes and periodontitis

Diabetes		
Chronic hyperglycemia [glucose in the blood]		
Symptoms	• Poly uria [frequent urination] • polyphagia [always hungry] • poly dipsia [always thirsty] • unexplained weight loss	
Diagnosis	Any of those 3 : 1- Symptoms + non fasting [casual / normal glucose] **≥ 200 mg/d** ** normal glucose can be taken any time of the day regardless of when the last meal was. 2- fasting glucose **≥ 126 mg/dl** ** fasting = no food for the last 8 hours ** normal fasting glucose = **70 – 100 mg/dl** 3- 2 hours post prandial oral glucose tolerance test **≥200 mg/dl** ** normal post prandial oral glucose **< 140 mg/dl**	
Types	**Diabetes type 1**	**Diabetes type 2**
	1- Used to be called insulin dependant diabetes 2- Autoimmune destruction of the insulin producing beta cells of the pancereas → insulin deficiency 3- Mostly children and young adults 4- Controlled by **insulin , diet and exercise**	1- MOST COMMON 2- Used to called non – insulin dependant diabetes 3- Insulin resistance OR increased glucose production by the liver OR impaired insulin secretion 4- Adult onset 5- Controlled by **oral drugs, diet and exercise**

****Gestational diabetes:** usually disappears after delivery but such women are at higher risk of developing type 2 after delivery

HBA1C testing

HBA1c = how much Hb was glycated over the last 3 months [was expressed as % now is mmol/ mol]

- **4-6 % = normal**
- **Less than 7 % = good control**
- **7-8% = moderate control**
- **More than 8% = need adjustment**

- **5% = 31 mmol/mol**
- **6% = 42 mmol/mol**
- **7% = 53 mmol/mol**
- **8% = 64 mmol/mol**
- **9% = 75 mmol/mol**

Diabetes complications

1- Retinopathy
2- Nephropathy
3- Neuropathy
4- Macrovascular disease
5- slow wound healing + susceptibility to infections

6- periodontitis

Oral manifestations of diabetes :

1- Reduce salivary flow
2- mucosal drying and cracking
3- burning mouth syndrome - BMS
4- periodontitis
5- caries and fungal (candida) infections

** diabetics have higher numbers of candida albicans and staphylococci

Periodontal disease in diabetics does not follows certain pattern but diabetes can lead to gingival proliferations , pedunculated polyps , abscess formation, periodontitis and loose teeth.

** diabetes alone will never cause periodontitis and diabetics with good plaque control will not have periodontal destruction. [diabetes only alters the host response to plaque]

Poor plaque control + poor diabetic control → faster tissue destruction and bone losss (gingival inflammation , deep pockets, bone loss , periodontal abcess)

Q: why do diabetics pts have greater risk of periodontal infection and infections in general?

- Hyperglycemia → altered PMN function [impaired chemotaxis and phagocytosis] → bac proliferation and higher susceptibility to infection
- Hyperglycemia → will alter the bacteria present (diabetics have more capnocytophagea, anaerobic bac, actinomyces species)

** diabetics do not have any changes in their antibodies [IgG, IgM, IgA]

IMP:

Hyperglycemia → non enzymatic glycosylation of protein and molecules → accumulated glycation end products [AGEs] → AGEs cross links with collagen → collagen becomes less soluble → impaired tissue healing + tissue is more susceptible to periodontal breakdown

Long duration of poorly controlled diabetics will cause vascular changes → contribute to periodontal destruction

AGEs:

- Reduce fibroblast formation
- reduce collagen synthesis
- Increase collagenase

AGEs occur at normal glucose levels but in diabetics AGEs formation is excessive

IMP: HBA1c and periodontitis are related (perio tx will reduce HBA1c by 0.4%)

Management of a diabetic patient

1- Measure glucose at every session
2- In long sessions measure throughout the procedure and whenever the pt feels symptoms of hypoglycemia (dizzy, tachycardia, sweating and confusion, tremors)
3- Establish good oral hygiene + remove calculus and correct any plaque retention factors + motivate to maintain good diabetic control.

**periodontal infections will worsen glycemic control → manage infections aggressively

** if periodontal surgery is need → HBA1C must be less than 7% [if the pt has poor diabetic control and surgery is needed you need to give prophylactic ABX – penicillin]

Genetic factors in periodontal disease

Genotype = the genetic composition **phenotype =** the shown traits [ex: curly hair, blue eyes etc]

- Monogenic = disease caused by a single gene
- Oligogenic / polygenic = disease caused by multiple genes
- Multifactorial = disease caused by genetic an environmental factors
- Loci = specific location on a chromosome

Associations of periodontitis with genetic and inherited conditions

1- **Hypophosphatasia →** deficiency in alkaline phosphatase → abnormal bone mineralization + cementum hypoplasia+ premature loss of teeth
2- **Papillon – LeFevre syndrome →** caused by mutations of cathepsin C gene → palmoplantar hyperkeratosis and periodontitis **[both dentitions affected]**
**** in some pts periodontitis is associated with AA.**
3- **Chedak higashi syndrome →** mutation in the LYST gene → abnormalities in neutrophils and periodontitis
4- **Leukocyte adhesion deficiency →** systemic infections + periodontitis
5- **Down syndrome →** almost all patients have periodontitis

- **Interleukin 1 [produced by activated monocytes]**: Mutations in IL-1 and its receptor antagonist genes have been associated with Periodontitis (in African Americans)
- **Periodontitis in Caucasians is more likely to occur in patients who have a genotype that effects IL-1 expression** that can result in a **fourfold increase in IL-1 production**.
- **Periodontitis is influenced by environmental risk factors, rather than solely by genetic factors**

Periodontal considerations in elderly

Common oral problems in elderly

1- Periodontal disease
2- Xerostomia
3- Edentulism
4- Caries
5- Oral / pharyngeal cancers

Clinical changes seen in elderly

1- Recession
2- Overjet becomes edge to edge contact
3- Attrition → increase in food table area
4- Missing teeth

Effect of aging on:

1- gingiva:
- Cell renewal happens at a slower rate → tissue is thin with reduced keratinization
- Functional and structural alterations in fibroblasts → affect healing

2- **Periodontal ligament:** defense ability against inflammation decreases
3- Cementum: increased cementum deposition **apically and lingually**
4- Alveolar bone : loss of bone mass
- Female patients with osteoporosis have greater levels of alveolar bone loss.
- **Estrogen therapy may reduce gingival inflammation and alveolar bone loss** but increases risk of breast cancer and myocardial infarction
- **Calcium and vitamin D supplements** in elderly with osteoporosis may reduce tooth loss

> Same amount of plaque causes more gingivitis in elderly when compared to younger pts [due to cellular and immune changes] – there is no difference in PMN between young and old pts
> Improvements in oral care may greatly reduce the incidence of pneumonia in elderly

Medications:

1- Calcium channel blockers , immunosuppressants and anticonvulsants → gingival overgrowth
2- Antidepressants , anticholinergics , anti hypertensives → dry mouth

Risk factors for periodontal disease in eldery:

A. Xerostomia: can be caused by medications, low fluid intake, disease and can cause caries and periodontal disease
B. Dexterity problems : physical disabilities decrease effective plaque removal
C. Estrogen deficiency: increases the risk of severe periodontitis and bone loss in post menopausal women
D. Smoking & alcohol

Sings of xerostomia:

1- Taste alterations
2- Dysphagia
3- Burning sensation
4- Difficulty with speech
5- Root caries

E. Lower serum folate level → greater levels of periodontitis

Management: reduce bacterial load by OH measures +

1- SRP – might need sub antimicrobial tetracycline
** dilute mouth wash with water so it is less irritating to the mucosa
2- Fluoride applications + saliva stimulants

When managing elderly consider:

1- Ability to effectively remove plaque
2- Medications
3- General health status
4- Ability to tolerate tx

Prognosis of periodontitis

Prognosis = a prediction of the probable course, outcome and duration of the disease – comes after diagnosis and before tx planning

Prognostic factors:

1- Age : If 2 pts have the same amount of CAL and destruction, the older pt has better prognosis [it took the younger pt shorter time to have the same amount of destruction]
2- Disease severity [Pocket depth , CAL, bone loss]
3- Plaque control
4- Pt compliance
5- Systemic factors
   A. Smoking – direct relationship exist between smoking and prevelance / incidence of periodontitis [smokers → poorer prognosis than non- smokers]
   B. Diabetes [diabetics → poorer prognosis , uncontrolled diabetes → poorer prognosis compared to control diabetes]
   C. Stress
6- Local factors:
   A. Plaque / calculus – presence and ability of the practitioner and pt to remove them
   B. Plaque accumulation areas [subgingival margins of restorations , overhangs ,developmental grooves , enamel pearls]
   C. Crown / root ratio [short roots with large crowns → poor prognosis]
   D. Tooth mobility [the greater the mobility the poorer the prognosis]

Good prognosis	Good control of etiological factors – tooth can be easily maintained by the dentist and the pt
Fair prognosis	25% CAL and/or class 1 furcation
Poor prognosis	50% CAL, class II furcation
Questionable prognosis	>50% CAL , class II or III furcation, poor crown root ratio , grade 2 or 3 mobility
Hopeless	Inadequate attachment to maintain function, comfort

Overall prognosis is established first then individual prognosis of certain teeth

Old classification of periodontal disease – aggressive and chronic periodontitis

Aggressive periodontitis	Chronic periodontitis
1- Rapid disease progression [CAL and bone loss] – 3 to 4 times faster than chronic periodontitis	1- Progression is slow but might have episodes of rapid progression
2- Familial aggregation [you know this from pt's medical history]	2- No familial aggregation
3- Etiological factors [plaque and calculus] are minimal compared to destruction seen	3- Etiological factors [plaque and calculus] commensurate with amount of destruction seen
4- Mostly in people less than 35 yo	4- Mostly in older pts above 55 yo
5- Clinical signs of inflammation might be minimal or absent	5- Clinical signs of inflammation usually commensurate with etiological factors
6- Patient is healthy [no systematic diseases]	6- Can be modified by systemic diseases [ex: diabetes]
7- Elevated levels of AA and P.Gingivalis + phagocyte abnormalities	

Localized aggressive periodontitis	Generalized aggressive periodontitis
1- Around puberty	**1- Mostly below 30 YO**
2- Strong antibody response	**2- Poor antibody response**
3- Localized CAL at first molars and incisors + interproximal CAL at 2+ perm teeth [one of which is the first molar] + the involvement of 2 or less other teeth	**3- Generalized interproximal CAL at 3+ permanent teeth [other than 1st molar and incisors]**
4- Distolabial migration of max incisors → diastema	**4- Gingiva might appear inflamed and red or free of any inflammation**
5- Vertical bone loss around first molars and incisors	**5- Some pts might have other systemic manifestations [weight loss, malaise etc]**
6- Arch shaped bone loss from distal of second premolar to mesial of second molar	**6- Bone loss affects the majority of the dentition**
**** more in African Americans**	
From mostly affected to least – black males –> black females –> white females –> white males	

Q: what causes the localized CAL in localized aggressive periodontitis?

1- AA colonize the first perm teeth to erupt [incisors + first molars] then the body immune defense is strong → prevents further sites from being affected
2- Other bacteria inhibit AA colonization → AA becomes localized
3- AA loses it's destruction ability for unkown reason
4- Defect in cementum formation

Localized periodontitis [localized CAL]

Causes :

1- Localized aggressive periodontitis
2- Cracks / splits in the root
3- Endo perio lesions [retrograde periodontitis]
4- Periodontal abscess
5- Acute ulcerative periodontitis [ANUP]
6- Anatomical defects [grooves on upper incisors]

Sings / symptoms:

Signs	Symptoms
Mobility	Loose teeth
Tooth migration	Teeth move to new locations / gaps between teeth
Pus	
Bone loss	Bad taste in the mouth

Types of bony defects that occur in localized periodontitis

3 wall bony defect	2 walls bony defect	1 wall bony defect	Crater/ cup defect
1 tooth surface and 3 bony surfaces	interdental crater 2 tooth surfaces and 2 bony surfaces	2 tooth surfaces 1 bone surface 1 soft tissue border	defect surrounds the tooth – several surfaces of the tooth + several surfaces of bone

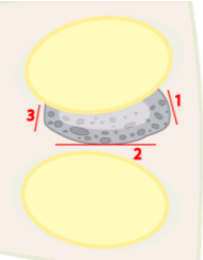

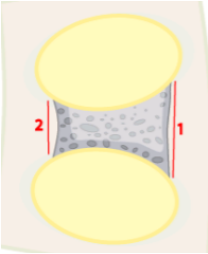

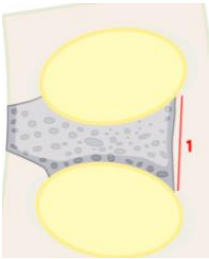

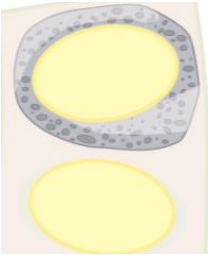

Treatment of periodontal disease

Treatment of periodontal disease should be done to :

1- Remove the cause
2- Reverse signs and symptoms
3- Stop disease progression
4- Restore normal gingival architecture
5- Regenerate destroyed tissue

Consent form

1- **Information about the procedure**
2- **Treatment plan**
3- **Cost**
4- **Prognosis and benefits**
5- **Possible complications and side effects**
6- **Alternative tx and it's cost**

Treatment of gingivitis / mild periodontitis

1- Limited Plaque control [show the pt the correct way of tooth brushing]
2- Remove supragingival calculus and plaque
3- Correct overhangs/ subgingival restorations and other plaque retention areas
4- Treat carious lesions [they act as niches for plaque accumulation so by sealing all carious lesions you decrease microbial load and plaque + treating carious lesions will make them more accessible to cleaning by the pt]
5- Comprehensive plaque control [tooth brushing and flossing]
6- If the pt has subgingival calculus → sub gingival scaling and root planning
7- **Re evaluate after 4 weeks [to allow epithelial + CT healing and for OH measure to reach their maximum effect]**

During re evaluation :

1- Reprobe all pockets
2- Check pt's OH maintenance
3- If the pt has CAL of 5 mm or more at re evaluation → refer to periodontist
   **** the cut – point for referring to a periodontist is 5 mm because the standard root length = 13 mm and the alveolar bone crest is 2mm below the bottom of the pocket → when CAL = 5mm → half of the root support remains**

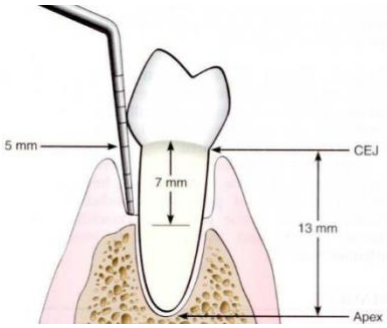

Treatment of moderate to severe periodontitis

Preliminary phase:

- Treat all emergencies [dental / periapical – periodontal]
- Extraction of all hopeless teeth [can be postponed]

Initial therapy: phase 1

1- Advise pt to reduce risk factors [quit smoking – improve glycemic control – better stress coping strategy]
2- OHI + explain the role of plaque
3- Strategic extractions
4- Detailed OH + re- inforcement
5- Occlusal adjustment of over erupted teeth

6- Try to find the cause of any areas with localized periodontitis [overhanging restorations, cracks, endo perio lesion etc..]
7- Supragingival + subgingival scaling and root planning [SRP]
8- Prescribe 0.12 % CHX mouthwash
[rinse with 10 ml for 1 minute twice daily for maximum of 2 weeks – rinse 30-45 mins after tooth brushing]
9- Temporize all carious lesions
10- Night guard [in case of tooth migration and bruxism]
11- Re – evaluation

** subgingival scaling and root planning need enough LA **[by regional block and local infiltration]** – inject a few drops of LA at the base of each papilla → control pain + reduce bleeding

Benefits of scaling root planning : we are removing the primary cause of periodontal disease [plaque and calculus covered with plaque] →

1- Reduce inflammation
2- Reduce bacteria number and bacteria become less pathogenic [from gram -ve anaerobes to gram +ve areobes]
3- Decrease probing depth and increase gain in attachment
4- Slow or stop disease progression

3 things you must consider if at re evaluation you still see sites with deep pockets and CAL:

1- Systematic disease and their effect [diabetes, stress etc.]
2- Anatomical factors that limit the pt's ability to perform good oral hygiene [root concavities , deep pockets and furcations]
3- Pt's compliance in maintaining oral hygiene and plaque control

Surgical phase [phase 2]: Surgeries for

1- periodontal regeneration
2- Gain access for cleaning root surfaces
3- Remove hyperplastic gingiva
4- Root resection / tooth hemisection

Restorative phase [phase 3] :

1- Ortho tx in case of teeth migration
2- RPD / FPD
3- Implants

Periodontal maintenance [phase 4 therapy] :

Cyclic recalls to :

- re probe pockets and compare to previous charts
- check OH and appearance of gingival tissues + pt's control of risk factors
- SRP

Localized CAL tx

- Severe localized periodontal defects that don't have an obvious endo cause [crack , PA radiolucency etc] → are considered to have periodontal in origin → do SRP etc ..
- Endo [pain, TTP , pus etc] → RCT first
- Crack → extract or root resection or hemisection

Periodontal medications

Most pts with periodontitis respond well to conventional therapy [plaque control , non surgical debridement etc..] some pts with aggressive or atypical forms of disease do not respond very well to conventional therapy and require antibiotics [ABX]

- **Antiseptic =** antimicrobial agent applied to mucous membranes / wound to kill microorganisms
- **Disinfectants =** a sub category of antiseptics that is applied to objects not human tissue

Many studies show that attachment gain at 6 months is 0.3-0.4 mm more if ABX are used with SRP.

Q: how do you decide which ABX to prescribe?

1- Pt history + signs and symptoms
2- Microbiological sampling [culture and sensitivity test results] to know what type of bacteria to target

ABX USED IN PERIODONTITIS YTEARTMENT

TETRACYCLINES	- Can concentrate in the periodontal tissue and inhibit the growth of AA - **Bacteriostatic** and anticollagenase effect - Concentration in the gingival crevice is 2-10 more than serum Side effects: 1- Photo toxicity 2- Nephrotoxicity 3- Teeth discoloration if administered to children below the age of 12 **Minocycline and doxycycline:** suppress spirochete and motile rods in periodontitis pts Less side effects [photo and nephron toxicity] Mino cycline can cause reversible vertigo **Minocycline dose = 200 mg/day for 1 week** **Doxycycline dose = 100 mg/ day** ** tetracycline absorption from the GIT is usually altered by calcium products and anti acids **– doxy cycline absorption is only slightly altered** compared to other tetracyclines ** **doxycycline is recommended in a sub antimicrobial dose to prevent collagenase (periostat)** **Sub antimicrobial dose for host modulation (periostat) =** 20 mg twice daily for 3 months ****There are new tetracyclines that have no antibiotic activity only anti-collagenase activity [host modulation therapy]**
METRONIDAZOLE	- **Bacterocidal** to **anaerobic bacteria** [p.gingivalis + p. intermedia] - Can be used to treat gingivitis, NUG, periodontitis

	- Effective against AA if combined with other ABX **Side effects:** **1- Anti abuse effect if combined with alcohol consumption [severe cramps, nausea, vomiting]** **** ask the pt to avoid alcohol during therapy and for at least 1 day after therapy is discontinued.** **2- Inhibits warfarin metabolism [prolongs prothrombin time]**
PENICILLIN	- **Bactericidal** - Penicillin other than amoxicillin and augmentin [amoxicillin + clavulunate potassium] don't increase clinical attachment gain. **Side effects:** 1- Allergic reactions 2- Bacterial resistance **Amoxicillin :** Dose = 500 mg 3 times daily for 8 days **Amoxicillin – clavulanate potassium: [augmentin]** ** addition of clavulanate potassium make it resistant to penicillinase producing bacteria [bacteria that is able to destroy penicillin] **Clindamycin:** Effective against anaerobic bacteria Used if the pt is allergic to penicillin Clindamycin can be used if periodontitis did not improve with tetracyclines **Dose = 300 mg 3 times daily for 10 days** **Side effects:** **Pseudomembraneous colitis** **Ciprofloxacin:** ** **the only ABX that is effective against all strains of AA** Used in combination with metronidazole **Side effects:** **1- Nausea + abdominal discomfort** **2- metallic taste in the mouth** **3- inhibits the metabolism of theophylline and caffeine [if administered together can lead to toxicity]** **4- enhances the effect of warfarin and other anticoagulants** **Azithromycin:** - effective against anaerobes **Dose: 500 mg once daily for 4-7 days** ** azithromycin is actively transported to the sites of inflammation by phagocytes then released directly into inflammation sites when phagocytes rupture during phagocytosis

ABX dosage		
Amoxicillin	**500 mg**	**3 times daily for 8 days**
Metronidazole		**3 times daily for 8 days**
Ciprofloxacin		**Twice daily for 8 days**
Azithromycin		**Once daily for 4-7 days**
Clindamycin	**300 mg**	**3 times daily for 10 days**
Doxycycline / minocycline	**100 -200 mg**	**Once daily for 21 days**
Combinations		
Metronidazole + amoxicillin	**250 mg of each 3 times daily for 8 days**	
Metronidazole + ciprofloxacin	**500 mg of each twice daily for 8 days**	

** pt's with high periodontal risk can benefit from taking low dose Aspirin **[100 mg / day] – as long as they don't have any medical contra indications** – Aspirin can decrease the rate of CAL and prevent cardiovascular disease.

Local drugs

Provide localized concentrations at effective level for sufficient time with minimal side effects
Usually used as an adjunct to SRP
They further decrease inflammation and pocket depth and increase attachment gain

Pocket irrigation	Pocket inserts
1- CHX solution 2- Elyzol [metronidazole gel]: - **oil based 25% metronidazole gel** - **Slightly viscous when applied in the pocket → becomes liquid by body's heat then hardens again forming crystals when it contacts water** 3- Minocycline microspheres [Arestin] : **2 % minocycline encapsulated in bioresorbable microspheres in gel** 4- Doxycycline gel [Artidox]: **10% doxycycline in a gel**	**1- CHX chip [perio chip]:** - Biodegradable gelatin that has 2.5 mg of CHX gluconate - Keeps CHX in concentrations above the tolerance level of bacteria - Resorbs on it's own after 7-10 days  **2- Tetracycline fibers :** Packed into the periodontal pockets to maintain tetracycline concentrations – needs to be removed after 10 days 

Important studies in periodontics:

- **Mattila** → reported a relationship between periodontal and cardiac disease
- **Offenbacher** → developed the term periodontal medicine

Periodontitis is related to :

1- Cardiovascular disease
2- Strokes
3- Diabetes
4- Obesity
5- Pre term low birth weight babies [PTLBW is a child born less than 37 week and less than 5 lb. 8 oz]
6- Pre eclampsia [hypertension and proteinuria – dangerous for both the child and the mother if it occurs after 20 weeks of gestation]
7- Renal disease
8- Nosocomial pneumonia
9- Pancreatic cancer
10- Osteoporosis
11- GIT diseases [subgingival plaque is a reservoir for H.pylori → gastric ulcers]
12- Rheumatoid arthritis
13- Erectile dysfunction
14- Prostatitis [inflammation of the prostate]
15- Alzhiemers

NUP & AIDS related periodontal disease

- NUP can be an extension of NUG into the periodontal tissues causing **CAL and bone loss**
- NUP is exclusively reported in immunocompromised pts.
- Both NUG and NUP show necrosis as a primary clinical feature
- NUG and NUP have the same predisposing factors

NUP clinical presentation

1- Necrosis + ulceration of the interdental papilla & gingival margin
2- Painful bright red gingival margin that bleeds easily
3- CAL + bone loss
4- DEEP INTERDENTAL CRATERS
5- Tooth mobility and tooth loss
6- Oral mal odor , fever, malaise lymphadenopathy

- **NO POCKETS** [ulceration will result in recession not pockets]
- NUP patients have fusi form – spirochete bacterial flora

HIV / AIDS related periodontal disease

Oral infections / neoplasms can be the first sign of HIV [many pts will not know they have HIV – or they will not tell you]

HIV gingivitis [linear gingival erythema]- LGE

Intense linear band of erythema of the gingival margin, usually extending 2-3mm apically from the gingival margin. Some patients have gingival pain.

Management = same as gingivitis [SRP + OHI + CHX pocket irrigation] then reevaluate after 2-3 weeks → if no improvement → candida infection [give systemic anti fungal **Fluconazole (Diflucan), 100-mg tablets: Take 2 tablets immediately, then 1 tablet daily for 7-14 days]**

Recall every 2-3 months

HIV NUG :

Management :

1- LA then debridement of the lesions using a cotton pellet soaked in 3% hydrogen peroxide [diluted with water]

- The patient should be seen daily or every other day for the first week; debridement of affected areas is repeated at each visit + plaque control methods are gradually introduced.
- Prescribe 0.12% CHX mouthwash
- Pt should avoid smoking , alcohol , spices
- If the pt has severe tissue destruction and / or systemic manifestations [fever, malaise , lymphadenopathy] → give ABX + prophylactic antifungal

2- After initial healing has occurred, the patient should be able to tolerate scaling and root planning if needed.

HIV NUP

Similar features to non HIV pts but more severe destruction is seen
Very rapid CAL and bone loss [can happen in weeks]
Large areas with Soft tissue necrosis and bone exposure and sequestration
Symptoms:

A. Spontaneous bleeding
B. Deep seated pain in the jaws [pt will tell you I feel that my teeth are hitting my jaw bone] – pain my happen before CAL
C. Loose teeth

Poor response to perio therapy
Management:

1- Debridement/ removal of necrotic tissue + Povidone-iodine (Betadine) irrigation (gives both relief of pain and control of bleeding)

- prescribe CHX mouthwash
- Systemic antimicrobials **Flagyl (metronidazole 250 mg, with two tablets taken immediately and then one tablet four times daily for 5-7 days)** to reduce pain and promote healing + Prophylactic topical or systemic antifungal .

2- follow up: Commence subgingival scaling, meticulous OHI needed (special OH devices)

candidiasis

Antifungal agents	
Topical	**Systemic**
1- Nystatin (Nilstat, Mycostatin) **A. Oral suspension –** rinse with one teaspoon x4 daily B. **Tablets –**dissolve one in the mouth x 4 or x 5 daily **C. Pastilles -** dissolve one in the mouth x 4 or x 5 daily D. **Ointment [mostly for angular chelosis] –** apply to the area X3 or X4 daily **2-** Fluconazole (diflucan) [oral suspension] **-** 200 mg first day followed by 100 mg once daily for at least 2 weeks. **3-** Amphotericin B (fungizone) - 100 mg X4 daily for 2 weeks	1- **Ketoconazole (Nizoral) ,200 mg tablets:** Take 2 tablets immediately, then 1 or 2 tablets daily with food for 5-14 days. 2- **Fluconazole (Diflucan), 100-mg tablets:** Take 2 tablets immediately, then 1 tablet daily for 7-14 days

HIV periodontitis : majority of HIV-positive individuals experience gingivitis and chronic periodontitis in a manner similar to the general population. They just need to maintain good OH

Periodontal abscesses

Periodontal abscess

Q**: What causes a periodontal abscess?** Anything that blocks / impairs the pocket drainage

1- Pre existing deep pocket or tortuous pockets [pockets that involve more than one surface of the root] → infection spreads from the pocket into the deeper Periodontal tissues
2- Blockage of a pocket opening by foreign body [popcorn shell, food debris, tip of a toothpick] or calculus
3- Trauma / ortho Tx without initial perio Tx
4- Supragingival scaling without sub scaling [since the supra calculus is removed the gingiva shrinks → narrow opening of the pocket → closes over the sub gingival calculus → blocked drainage → abscess]
5- RCT Perforation / fracture - the bacteria will be carried from the canal into the PDL
6- Poorly controlled Diabetes **

ACUTE PERIODONTAL ABSCESS: ***OFTEN AN EXACERBATION OF A CHRONIC PERIODONTAL LESION***

CLINICAL APPEARANCE	• ovoid elevation along the lateral aspect of the root • red swelling with smooth shiny surface [if the pt is a smoker the gingiva will be more fibrotic → the abscess surface will not be red and shiny. It will be dull and firm domelike elevation] • **puss can be expressed from the gingival margin with gentle pressure**
SIGNS AND SYMPTOMS	1- pain and discomfort 2- localized swelling ** 3- tooth is elevated in the socket + TTP ** 4- exudate 5- mobility 6- fever and regional lymphadenopathy
TREATMENT	1. relief pain + stop spread of infection by analgesics and ABX 2. establish drainage : A. through pocket: LA + topical anesthesia and insert a curette into the pocket to establish drainage. B. Incision in the tissue if fluctuant : LA → vertical incision from mucobuccal fold to gingival margin with #15 blade + separate the tissue with a curette or periosteal elevator → express fluctuant matter → re approximate wound edges with a moist gauze + light pressure [no need for sutures] C. Lesion is large and drainage cannot be established : give ABX until major signs subside then do SRP ** do not use ABX alone without drainage 3. If the tooth is extruded → slight occlusal adjustment to avoid contact with opposing and relief pain ** if the tooth is mobile → extraction 4. Instruct pt with rinse with CHX and warm salt water + avoid exertion and stay hydrated

CHRONIC PERIODONTAL ABSCESS

CLINICAL APPEARANCE	**Puss draining through a sinus tract or through the pocket**
SIGNS AND SYMPTOMS	1- fistula / sinus tract [the sinus might be covered with a small beadlike mass of granulation tissue] ** 2- slight tooth elevation 3- intermittent exudation ** 4- no pain or dull pain ** 5- no systemic involvement **
TREATMENT	SRP [surgical treatment in case of deep furcation or vertical defects that cannot be instrumented properly]

Q: how do you diagnose a periodontal pocket?

1- History + clinical and **radiographical features [alveolar bone loss]**
2- Probe all tooth surfaces around the gingival margin to detect a channel from the marginal area to the deeper periodontal tissue
** the abscess might not be located on the same surface of the root as the pocket it formed from [a facial pocket might cause an interproximal abcess]

Gingival abscess:

GINGIVAL ABSCESS

CAUSE	bacteria carried deep into the tissue when a foreign substance [tooth brush bristle, lobster shell, apple core etc] is forcefully embedded into the gingiva
SIGNS AND SYMPTOMS	1. Sudden onset , localized painful , rapidly expanding swelling confined to the gingival margin or interdental papilla 2. Early stages appears as red swelling with smooth shiny surface after 24-48 hours → become fluctuant and puss can be expressed [if left un treated it might rupture spontaneously] **3. Adjacent teeth are tender to percussion** **4. NO POCKET [NO CAL OR BONE LOSS]** 
TREATMENT	LA → SRP to establish drainage and remove debris OR If the swelling is fluctuant → incision with a #15 blade + remove any foreign material and irrigate the area with warm water + apply light pressure with a moist gauze Once bleeding has stopped instruct the pt to rinse with **warm salt water every 2 hours for the rest of the day.** Re asses after 24 hours → if enough resolution do SRP

PERICORONAL ABSCESS

CAUSE	retention of plaque, food impaction or trauma → inflammation of the operculum covering a partially erupted tooth [mostly mand 3rd molars] **pericoronal abscess is always associated with a pseudo pocket**
TREATMENT	LA → lift the operculum with a curette and remove the underlying debris + irrigate with saline instruct the pt to rinse with **warm salt water every 2 hours for the rest of the day.** Re asses after 24 hours Give analgesics + ABX if there are any systemic signs [fever, lymphadynopathy etc] Once the acute phase subsides → operculectomy [if the tooth is covered by ST distally] or extraction of the tooth [if part of the tooth is still inside the bone]

Gingival abscess	Periodontal abscess
- Occurs on Marginal gingiva - Disease free sites [healthy gingiva] - Caused by forceful impaction of a foreign body with bacteria deep into the tissue	- Occurs on Lateral surface of the root - Pt mostly has periodontitis [CAL and bone loss] - Caused by blockage of the pocket drainage by calculus, foreign body

Peri apical abscess	Periodontal abscess
- Severe pain **that is not responsive to analgesics **** - **TTP **** (Tender to Percussion) - **Swelling is in the muco buccal fold** - **May or may not have a pocket – if draining through the PDL the opening is small** - **Sinus tract is located apical to MGJ** - Bone loss is around the apex - Non vital tooth **** might drain through a pocket or through bone →** sub periosteal swelling	- **Mild to moderate pain** that responds well to analgesics - May or may not have TTP (Tender to Percussion) - Swelling is on the gingiva - Opening into the PD is wider - Sinus tract is located at the gingiva or mucogingival junction - **Bone loss is lateral to the tooth or root surface** - **Vital tooth**

ABX indications :

1- **Cellulitis / spreading infection**
2- **Deep in accessible pocket**
3- **Immune compromised pt**
4- **Fever + malaise + lymphadynopathy**

Amoxicillin *1.0-g loading dose, then 500 mg three times a day for 3 days - Re-evaluation after 3 days to determine need for continued or adjusted antibiotic therapy*

Penicillin Allergy :

- **Clindamycin** 600-mg loading dose, then 300 mg four times a day for 3 days
- **Azithromycin (or clarithromycin)** 1.0-g loading dose, then 500 mg once daily for 3 days

New periodontal classification 2017

Periodontal diseases and conditions										
Periodontal health Gingival diseases and conditions			Periodontitis			Other conditions affecting the periodontium				
Periodontal health and gingival health	Gingivitis: Dental biofilm induced	Gingival disease: Non dental biofilm induced	Necrotizing periodontal diseases	Periodontitis	Periodontitis as a manifestation of a systemic disease	Systemic diseases or conditions affecting the periodontal supporting tissues	Periodontal abscess and endo perio lesions	Mucogingival deformities and conditions	Traumatic occlusal forces	Tooth and prosthesis related factors

Peri implant diseases and conditions			
Peri implant health	Peri implant mucositis	Peri implantitis	Peri implant soft and hard tissue deficiencies

1- **Periodontal health Gingival diseases and conditions**

Periodontal health and gingival health : [free of inflammation]

A. **Gingival health on intact periodontium**
B. **Gingival health on reduced periodontium :**
   Stable periodontitis patient:
   Non periodontitis patient: ex - recession / crown lengthening

- pristine clinical health = no CAL , no BOP , no sulcular depth more than 3 mm , no sings of inflammation
- clinical health = no or minimal clinical signs of inflammation

Gingivitis : dental biofilm induced

A. **associated with dental plaque alone:**
B. **mediated by systemic or local risk factors :**
   systemic – diabetes, smoking, malnutrition, puberty, pregnancy, oral contraceptives ,leukemia]
   local – plaque retention factors + hyposalivation
C. **Drug influenced gingival enlargements:**

	Health	Gingivitis
Intact periodontium	No CAL [pockets less than or equal to 3 mm] No bone loss	
Reduced periodontium	CAL [pockets less than or equal to 3 mm] Possible bone loss	
Stable periodontitis pt	CAL Bone loss Pocket less than or equal to 4 mm	CAL Bone loss Pocket less than or equal to 3 mm

**** BOP 10-30 % → local gingivitis** **BOP > 30% → generalized gingivitis**

Gingival disease: Non dental biofilm induced [genetic disorders, infections, immune conditions, neoplasms , gingival pigmentation , traumatic lesions , metabolic diseases , **vitamin C deficiency**]

ISO probe specifications:

1- Tip diameter = 0.5 mm
2- Cylindrical tine structure
3- Constant force limiter of 0.25 N
4- Taper = 1.75°
5- 15 mm markings

2- Periodontitis :

Necrotizing periodontal diseases: [all have papilla necrosis, bleeding, pain + impaired host response]

A. NUG
B. NUP
C. Necrotizing stomatitis : necrosis extends beyond the gingiva causing denuded bone regions

Periodontitis as a manifestation of a systemic disease: Ex: papillon le fever syndrome [has an early manifestation of periodontitis]

Conditions affecting the periodontal tissues independently of plaque induced inflammation : neoplasms affecting the periodontium

Periodontitis : pt is a periodontitis case if:

1- Has interdental CAL at 2 or more non adjacent sites OR
2- Buccal CAL 3mm or more with pocketing over 3mm is detected at 2 or more teeth + observed CAL can't be attributed to:
   A. Gingival recession due to traumatic occlusion
   B. Caries extending to the cervical region of the teeth
   C. CAL distal to the second molar associated with mispositioned or extraction of a 3rd molar
   D. Endo lesion draining through the marginal periodontium
   E. Vertical root fracture

Goals of periodontitis staging:

A. Classify severity and extent
B. Asses complexity

Goals of periodontitis grading:

A. Estimate future risk of periodontitis
B. Estimate potential health impact of periodontitis

	Periodontitis	Stage I	Stage II	Stage III	Stage IV
Severity	Interdental CAL *(at site of greatest loss)*	1 – 2 mm	3 – 4 mm	≥5 mm	≥5 mm
	RBL	Coronal third (<15%)	Coronal third (15% - 33%)	Extending to middle third of root and beyond	Extending to middle third of root and beyond
	Tooth loss *(due to periodontitis)*	No tooth loss		≤4 teeth	≥5 teeth
Complexity	Local	• Max. probing depth ≤4 mm • Mostly horizontal bone loss	• Max. probing depth ≤5 mm • Mostly horizontal bone loss	In addition to Stage II complexity: • Probing depths ≥6 mm • Vertical bone loss ≥3 mm • Furcation involvement Class II or III • Moderate ridge defects	In addition to Stage III complexity: • Need for complex rehabilitation due to: – Masticatory dysfunction – Secondary occlusal trauma (tooth mobility degree ≥2) – Severe ridge defects – Bite collapse, drifting, flaring – <20 remaining teeth (10 opposing pairs)
Extent and distribution	Add to stage as descriptor	For each stage, describe extent as: • Localized (<30% of teeth involved); • Generalized; or • Molar/incisor pattern			

	Progression		Grade A: Slow rate	Grade B: Moderate rate	Grade C: Rapid rate
Primary criteria *Whenever available, direct evidence should be used.*	Direct evidence of progression	Radiographic bone loss or CAL	No loss over 5 years	<2 mm over 5 years	≥2 mm over 5 years
	Indirect evidence of progression	% bone loss / age	<0.25	0.25 to 1.0	>1.0
		Case phenotype	Heavy biofilm deposits with low levels of destruction	Destruction commensurate with biofilm deposits	Destruction exceeds expectations given biofilm deposits; specific clinical patterns suggestive of periods of rapid progression and/or early onset disease
Grade modifiers	Risk factors	Smoking	Non-smoker	<10 cigarettes/day	≥10 cigarettes/day
		Diabetes	Normoglycemic/no diagnosis of diabetes	HbA1c <7.0% in patients with diabetes	HbA1c ≥7.0% in patients with diabetes

3- **Other conditions affecting the periodontium**

Systemic diseases or conditions affecting the periodontal supporting tissues independent of plaque induced periodontitis : example neoplasms

Periodontal abscess and endo perio lesions : endo perio lesiosn that are associated with trauma or iatrogenic damage → poor prognosis [ex: pulp necrosis draining through the periodontium , external root resorption, root fracture, perforations]

Periodontal phenotype = gingival phenotype [gingival thickness + keratinized tissue width] + bone morphotype [thickness of the buccal plate]

CAL CAIRO CLASSIFICATION

RT 1	Gingival recession with no interdental CAL
RT 2	Interdental CAL is less than or equal to buccal CAL
RT 3	Interdental CAL is greater than buccal CAL

Occlusal considerations in periodontics

Tooth support is obtained by 5 mechanisms :

1- **Periodontal ligament fibers [tensional theory]:** when force is applied principle fiber bundles straighten and transmit forces to the bone
2- **Fluid displacement :** flow of extracellular fluid between PDL and bone marrow spaces through the cribriform plate
3- **Bone elasticity**
4- **Tooth / root anatomy**
5- **Protection :** through proprioception fibers in the PDL

Trauma from occlusion

- **Trauma from occlusion :** high occlusal load beyond what the periodontium can withstand leading to altered position and stability of the tooth
- **Acute occlusal trauma** : results from suddenly biting on a hard object → pain + TTP + mobility
  ** restorations that alter the direction of occlusal forces can cause acute trauma
- **Chronic occlusal trauma :** gradual changes in occlusion caused by parafunctional habits
  - **Primary trauma from occlusion:** tissue reaction around a tooth with normal periodontium height
  - **Secondary trauma from occlusion :** tissue reaction around a tooth with reduced periodontium height
    ** this is no longer use because the changes that occur in the tissue are the same regardless of the attachment level

Q: why do teeth subjected to occlusal trauma become more mobile ?

- The first reaction to increase occlusal loading is increased vascularity in PDL space → collagen fibers lose their connections b/w cementum and bone →compressible PDL → tooth mobility
- After increase in vascularity , osteoclasts cause bone loss → widening of PDL → further increase mobility .

Forces :

Zone of pressure	Zone of tension
Thrombosis **Destruction of collagen + bone + cementum**	**Collagen and bone deposition**

Tipping movement [unidirectional]	Bodily movement [unidirectional]	Jiggling forces [multidirectional]
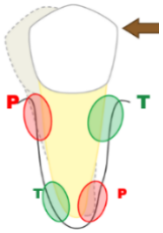	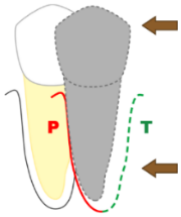	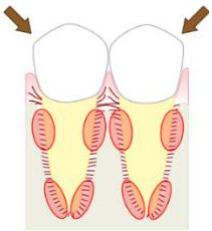

- In unidirectional forces like in ortho tx → the periodontium adapts and changes the tooth position
- In multidirectional forces like bruxism / occlusal trauma → jiggling forces → **both pressure and tension zones are present in the same areas of the PDL** → gradual widening of PDL + tooth mobility

Signs of occlusal trauma:

1- Tooth mobility
2- Tooth migration
3- Wear facets and evidence of bruxism
4- TTP
5- Sensitivity to hot / cold
6- Premature occlusal contact
7- Crown or root fracture
8- Widening of the periodontal ligament space in radiographs
9- Bone loss (inside of socket wall, NOT loss of bone height)

Physiological tooth mobility	Pathological tooth mobility
– Mobility is highest on waking [caused by extrusion of the tooth because of limited occlusal contact during sleep] then mobility decreases progressively during day – During the waking hours, mobility is reduced by chewing and swallowing forces, which intrude the teeth in the sockets. – Single-rooted teeth have more mobility than multirooted teeth; **<u>incisors have the most mobility.</u>**	Increasing loads on teeth causing bone resorption - Bruxism, Clenching, High restoration (iatrogenic) – Loss of periodontal attachment – Periodontitis – Root resorption – Apical periodontitis – Tumors/cysts Systemic causes: 1- Pregnancy 2- Scurvy 3- Diabetes 4- Scleroderma

**There is no direct relationship between the amount of attachment loss and the degree of tooth mobility.

Calculus bridge is considered to be a natural splint for teeth

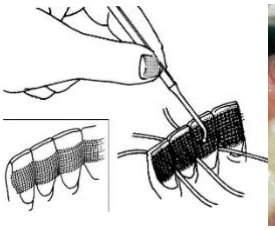

Tx of mobile teeth [splinting]:

1- Take tooth out of occlusion
2- Leave room for interproximal hygiene
3- Re inforce teeth with a splint

- Plaque that initiates gingivitis and leads to periodontal pocket formation affects the marginal gingiva, but **trauma from occlusion occurs in the supporting tissues [PDL] and does not affect the gingiva - The marginal gingiva is unaffected by trauma from occlusion because its blood supply is not affected**
- **Even when the vessels of the periodontal ligament are obliterated by excessive occlusal forces- trauma from occlusion does not cause pockets or gingivitis.**
- If inflammation is only in the gingiva [gingivitis] – the inflammation will not be affected by occlusal trauma
- If inflammation spreads from gingivitis to periodontitis → the inflammation is affected by occlusal trauma [zone of co- destruction]

**** animal studies found that traumatic occlusion did NOT increase periodontitis induced CAL**

Effect of trauma from occlusion on a pt with periodontitis

Zone of co- destruction: occurs in a tooth that has periodontitis and also has traumatic occlusion → more severe bone loss.

1- **Trauma from occlusion alters the alignment of transseptal and alveolar crest fibers** → changes the pathway of inflammation → inflammation directly passes to the PDL → infrabony pockets + crater like defects and tooth mobility
2- **Trauma from occlusion changes the shape of the alveolar crest** → widening of the marginal PDL + narrowing of the interproximal bone + shelf like thickening of the alveolar margin [lipping]

Occlusal trauma on a healthy or reduced periodontium periodontium	Occlusal trauma on reduced and inflamed periodontium	Occlusal trauma on reduced and inflamed periodontium [infrabony pocket]
Combined pressure and tension zones → collagen resorption+ bone and cementum resorption → progressive tooth mobility Ligament adjusts gradually **[no CAL]** Occlusal adjustment stabilizes the PDL width → teeth stabilized with normal mobility	A widened periodontal ligament and increased tooth mobility **[no CAL]** Occlusal adjustment stabilizes the PDL width → **reduced but not normal mobility**	increasing tooth mobility may also be associated with **increase CAL.** Occlusal adjustment will result in narrowing of the ligament space + less tooth mobility but CAL cannot be regained

- In a healthy periodontium, neither unilateral nor jiggling forces can result in attachment loss or pocket formation
- Factors that control the position of the teeth = periodontium + forces exerted on teeth.

In cases of pathological tooth migration you need to think of : [any change in those factors can lead to tooth migration]

1. Tooth morphologic features and cuspal inclination
2. The presence of a full complement of teeth
3. The physiologic tendency of teeth toward mesial migration
4. The nature and location of contact point relationships
5. Proximal, incisal, and occlusal attrition
6. The axial inclination of the teeth

Granulation tissue inside pockets applies forces that cause tooth migration

- Teeth may return to their original positions after the pockets are eliminated but if destruction is more on one side of a tooth than the other, **healing tissues tend to pull in the direction of the lesser destruction**

Endo – perio lesions

Communication between the pulp and the periodontium can occur through:

1- Apical foramen
2- Lateral canals [mostly in the apical 3rd of the root or in the furcation area]
3- Dentinal tubules [in case the cementum has been removed and dentine is exposed]
4- Perforations [worst prognosis is perforations in the coronal 3rd of the root or in furcation areas]

- **Retrograde periodontitis :** pulpal necrosis and bacteria moving from the apical foramen to the marginal gingiva
  Ex: An untreated pulpal necrosis is considered to be a local modifying risk factor for periodontitis by lateral accessory canals and apical foramen → aggrevate pocket formation + bone loss
- **Marginal periodontitis:** the disease proceeds from gingival margin towards the apex
  Ex: periodontitis → inflammation could reach the pulp by lateral canals, DT or apex

Effect of perio tx on the pulp: During root planning → DT exposure or damage to the BVs → can cause **transient pulp inflammation** [perio tx rarely leads to pulpal necrosis]

If blood supply is not impaired → pulp is not affected

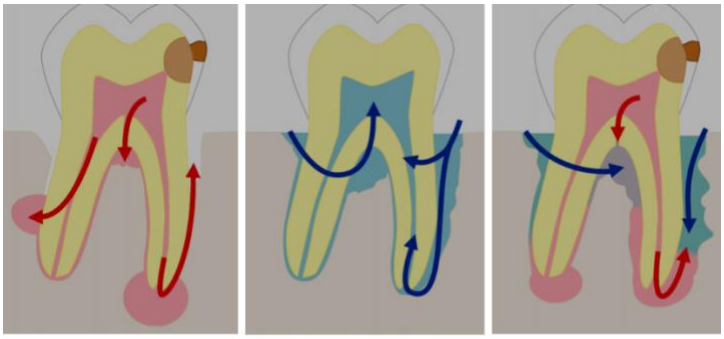

1- Primary endodontic lesion:

Pulpal necrosis [-ve pulp test] can cause bone resorption + inflammation in the periodontium apically / laterally or in the furcation area

Signs / symptoms [SI/SY]:

1- Pain +TTP
2- Mobility
3- **Swelling of the marginal gingiva** [the sinus tract opens into the gingival sulcus causing a swelling that looks like periodontal abscess]
4- **Tract that can be traced to the apex with a GP or probe , or as a through and thorugh furcation**

Treatment: RCT – the sinus tract will resolve alone

2- Primary endodontic / secondary periodontal lesion:

Pulpal necrosis [-ve pulp test] can cause bone resorption + inflammation in the periodontium apically / laterally or in the furcation area + drainage into the sulcus. Plaque + calculus follow the path of the tract → periodontal involvement

Signs/ symptoms:

1- Plaque and calculus in the pocket
2- Angular bone loss

Treatment : RCT + perio [SRP]

3- Primary periodontal lesion:

A pocket that reaches the apex – there might be a periodontal abscess in the acute phase

Signs / symptoms:

1- Bone loss + CAL down to the apex or the furcation area [wider bone defect compared to primary endodontic lesions]
2- Vital pulp
3- Tooth mobility

Treatment: perio tx [SRP]

4- Primary periodontal secondary endodontic lesion:

Periodontal inflammation reaches the pulp through lateral canals or DT

The only difference from primary endo secondary perio is the sequence [difficult to distinguish clinically]

Treatment : endo and perio tx **[perio tx alone might cause pulp necrosis]**

5- True combined lesion:

Endo occurs alone and perio occurs alone then they meet somewhere along the root

Poor prognosis – prognosis depends on extent and management of perio disease

Treatment: RCT and Perio

6- Concomitant pulpal and periodontal lesions :

Endo and perio lesions that don't have the same causative factors

Treatment: RCT and Perio

Q: how can you do differential diagnosis in Endo perio lesions ?

1- do pulp testing [inaccurate because +ve might mean the pulp is inflamed]
2- you can do a cavity test to look for internal cracks [use methylene blue]
3- take multiple radiograph in different angles
4- periodontal surgery to explore in case of vertical root fracture

Endo perio lesions DD:

1- Vertical root fracture:

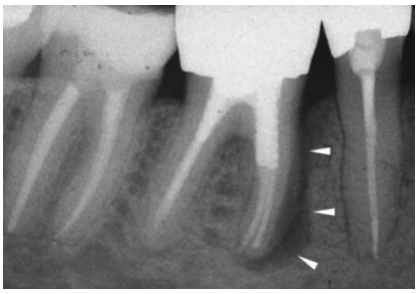

- Occurs from heavy condensation forces during endo or incorrect placement of posts
- **May occur as true combined lesion**
- May not show bone resorption or may have severe bone resorption [J-shaped radiolucency]
- May not be apparent radiographically and have only a narrow pocket

Treatment:

Single root → extraction

Multirooted teeth → hemisection or root resection

2- Lateral periodontal cyst

Less than 1 cm in diameter – well defined round radiolucency on the lateral aspect of the root causing swelling that is tender to palpation

Most in mand premolars and canine

**in pulpal disease bone loss is wider apically but in periodontal the apex is not usually involved

Gingival overgrowth

- **Overgrowth =** the enlargement of the gingiva as long as the stimulus is still present
- **Neoplasia =** enlargement that continue even after the stimulus is removed

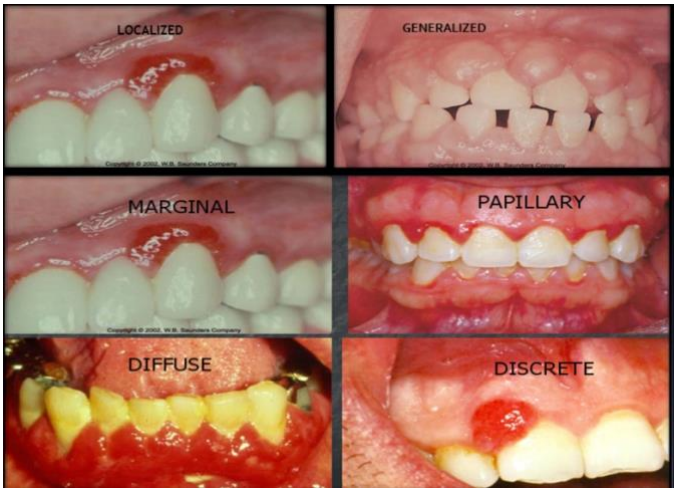

Gingival overgrowth:

Inflammatory

A. Acute [abscess]

Gingival abscess

- Sudden onset - Localized – painful – rapidly expanding – adjacent tooth is tender
- Limited to interdental papilla or gingival margin
- Early stages : red swelling with smooth shiny surface becomes fluctuant in 24- 48 hours [can rupture spontaneously]
- Caused by forceful impaction of food into the gingiva

Periodontal abscess

- Localized accumulation of pus - caused by food impaction and deep pockets
- Enlargement in the gingival 2/3 and involves the periodontal supporting tissues

Grade 0 = no enlargement

Grade 1 = enlargement confined to interdental papilla

Grade 2 = enlargement involving interdental papilla and marginal gingiva

Grade 3 = enlargement covering ¾ or more of the crown

B. Chronic – **MOST COMMON** - Bleeding + edema+ ballooning of interdental papilla due to prolonged exposure to dental plaque

Mouth breathing gingival enlargement [chronic inflammatory]:

- Mainly in the maxillary anterior segment → red edematous diffuse shiny surface
- **Non responsive to periodontal treatment**

Fibrotic

A. Drug induced :

- Painless, firm, pale pink beadlike enlargements of the interdental papilla that extend to the facial and lingual margins
- Maxillary and mandibular anterior regions
- **NO TENDENCY TO BLEED IF THERE IS NO INFLMMATION**

Drugs that cause enlargement:

1- **Phenytoin : anticonvulsant** to treat epilepsy – causes proliferation of fibroblast like cells and epithelial cells → enlargement
2- **Cyclosporine: immunosuppressant** used in autoimmune diseases and organ transplants – forms abundant extracellular matrix → enlargement
3- **Calcium channel blockers: Nifipdipine** used in treatment of angina, hypertension and arrythmias [can be combined with cyclosporine → more severe enlargement]

- Plaque still needs to be present to cause the enlargement – the drug only modifies the host response to plaque - Gingival overgrowth **NOT** related to dosage, concentration and duration

B. Idiopathic : hereditary gingival fibromatosis

- **Usually only one jaw is affected** – causes altered or delayed tooth eruption
- **Overgrowth completely covers the teeth**
- **Enlargement is pink , firm and leathery in consistency with pebbeled surface**
- **Can be part of a syndrome or appear separately**
- **The lesions develop irrespective of effective plaque removal.**

Combined [inflammatory + fibrotic]

Conditioned enlargements

A. Hormonal [pregnancy or puberty] :

Progesterone and estrogen hormones reach levels 10 and 30 times the levels of normal by the end of the third trimester → increase vascular permeability → increase inflammatory response to plaque + edema

Pregnancy epulis: [NOT A NEOPLASM]

- usually appears after the 3rd month of pregnancy
- Discrete **mushroom like flattened** mass that protrudes from the gingival margin or interproximal space – **regresses after delivery**
- **Can be prevented by maintaining good OH during pregnancy**
- Scaling and root-planing procedures + adequate OH → may reduce the size of the enlargement.
- Gingival enlargements shrink after pregnancy, but usually do not disappear.
- After pregnancy, the entire mouth should be reevaluated, a full set of radiographs taken, and the necessary treatment undertaken.

Lesions should be removed surgically during pregnancy only if they interfere with mastication

B. Nutritional : scurvy (scorbutic gingivitis)

Acute vitamin c deficiency → haemorrhage + collagen degeneration + edema of gingival CT→ modify pt's response to plaque → exaggerated inflammation + enlargement
** vitamin c deficiency does not cause inflammation
Appearance:

- marginal , bluish red gingiva
- smooth + friable + shiny
- **spontaneous bleeding**
- **surface necrosis with pseudo membrane formation**

C. Plasma cell gingivitis :

- Red friable gingival enlargement – granular + bleeds easily [cause by allergic rxn to dentifrices, chewing gums, or certain diet components] – **lesion resolves when you stop the exposure**

D. Non specific conditioned enlargements : pyogenic granuloma – similar to pregnancy epulis

1- Systemic diseases enlargements

A. Leukemia :

- gingiva becomes soft edematous and swollen + spongy and bleeds easily
- pallor in the surrounding mucosa
- gingiva is **purplish**

cyclic neutropenia: enlargements that occur with **low neutrophil count**

B. Granulomatous diseases : Wegener's granulomatosis

Strawberry gums ***

2- Neoplastic :

A. Benign [fibroma, papilloma]

B. Malignant

- kaposi's sarcoma – most common oral malignancy – associated with AIDs
- malignant melanoma [darkly pigmented – occurs in the hard palate + maxillary gingiva]

3- False enlargements

A. Underlying osseous lesion [tori and exostoses, paget's, cherubism]

B. Underlying dental tissue [during eruption]

Management of enlargements

Phase I	Phase 2
• Scaling • Root planning • Oral hygiene instructions • Drug substitution	• **Genioplasty** • **Gingivectomy** A. Conventional B. Laser [best - Diode laser and Nd:YAG LASERS] C. Electrosurgery D. Chemosurgery [5% formaldehyde or potassium hydroxide] – worst one because you cant control the chemical • **Flap + gingivectomy**

Management of furcation involvement

Anatomy of furcations between the first and third molars:

- The tooth roots get progressively shorter
- The space between the roots is smaller and fusion of roots is more common.
- The roots divide more apically (longer root trunk)
- Access is difficult for both pt and dentist

Furcation classification

Class 1	**Horizontal loss of periodontal tissue less than 3 mm**
Class 2	**Horizontal loss of periodontal tissue more than 3 mm but not encompassing the total width of the furcation**
Class 3	**Through and through destruction**

Causes of furcation involvement:

1- Periodontal disease
2- Endo perio lesions
3- Pulpal pathology spreading through the lateral accessory canals
4- Root surface concavities / enamel pearls + projections

Complications due to furcation involvement:

1- Un esthetic
2- Root caries
3- Plaque accumulation / Food impaction + difficult to clean
4- Reduce tooth prognosis

Q: Before managing any furcation involvement what should you consider?

Tooth related factors	Pt related factors
1- Furcation grade 2- Crown root ratio 3- Degree of root separation 4- Root anatomy **5-** Tooth mobility	1- Importance of the tooth in relation to the over all plan 2- Function and esthetic demands 3- Pt risk factors 4- OH 5- Financial consideration and long term prognosis

FURCATION GRADE	TREATMENT
GRADE 1	1. Scaling + debridement (with /without surgical access) 2. Furcation plasty [odontoplasty] - [remove inflammatory tissue → widen furcation entrance → bone level is remodeled and lowered so it's at the level of the furcation entrance to enhance pt's ability to clean it]
GRADE 2	1- Scaling and debridement (with/without surgical access) 2- Osteoplasty,odontoplasty 3- Pocket elimination [removing soft tissue and lowering the gingival level to provide access to clean the furcation] 4- GTR Regeneration **[best results with mandibular grade 2 furcations]**
GRADE 3	1- Scaling and debridement (with/without surgical access) 2- GTR Regeneration [in selected cases – not the treatment of choice] 3- Odontoplasty (furcation-plasty) 4- Tunnel preparation [surgically expose the furcation and make it accessible 5- Root-resection 6- Extraction / implant replacement

Factors to consider for root resection:

1- Divergence or fusion of the roots
2- Length + shape of the root
3- Bone remaining
4- How heavily restored the crown is

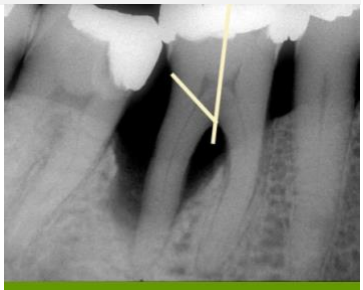

Hemisection vs root resection

Contraindications for root resection:

1- advanced bone loss on remaining roots
2- fused roots
3- Large existing restoration
4- difficult endo on remaining root(s)
5- cost (endo, advanced restorative).

Hemisection: dividing a multi rooted tooth to 2 small teeth

Most root-resected molars will survive for 5 years anything beyond that is a bonus

Dentinal hypersensitivity - DH

Dentinal hypersensitivity: short sharp pain that arises from exposed dentine in response to hot/ cold or sweet

- mostly affected teeth = canines and premolars
- SRP can cause transient hypersensitivity for 1-3 weeks or after bleaching
- In order for a pt to develop DH two processes must happen:
  A. **Lesion localization** [the dentine has to be exposed]
  B. **Lesion initiation** [the DT have to be open]

Exposure of dentine alone does not lead to hyper sensitivity – the pt starts to develop hypersensitivity when the DT are open

Explanation of how DH happens: Hydrodynamic theory: fluid inside DT is disturbed by mechanical , thermal or chemical means → stimulates baro receptors inside the DT → pain

- drying the exposed dentine → fluid will move towards the dry surface → stimulates nerve fibers
- Heat will expand the DT fluid , cold will shrink the DT fluid → stimulate nerve fibers
- Sugar / acid / sugar → fluid will flow towards the higher concentration → stimulate nerve fibers

Most common triggers for DH = cold and air

Causes of DH

1- **Gingival recession : due to**
   A. Pt's age
   B. Anatomy of the labial cortical plate [the thinner the bone → the more the recession]
   C. Tooth brush abrasion [alone it will not cause recession, the underlying bone has to be thin]
   D. Poor OH → gingivitis → periodontitis and recession
   E. Low frenum attachment [the frenum is attached close to the gingival margin , which mastication and speech the frenum will pull the gingival margin down → recession]
2- **Loss of enamel : due to**
   A. Tooth brush abrasion
   B. Attrition
   C. Erosion
   D. Abfraction

Q: how do you diagnose DH? By exclusion of other causes of transient tooth pain – Differential diagnosis of DH:

1- Caries
2- Fractured tooth – check by trans illumination or making the pt bite on a stick [pain on releasing → cracked tooth]
3- Leaking or fractured restorations
4- Pulpal pathology

DH examination

- Tactile test passing - exploratory probe by an explorer on the exposed dentine in a mesio distal direction – examine all teeth in the area where the pt complains of pain
- Air blast test – a jet of air over the area if sensitivity [the adjacent teeth should be covered]
- Cold water test – cold water in a syringe is placed slowly over the tooth surface

Desensitizing agents	
At home products	**In office products**
A. Products the block the nerve response : **5% potassium nitrate** B. Products that occlude the DT : Ex: strontium / stannous fluoride **They either deposit an occluding layer on top of the exposed dentine or deposit and occluding layer inside the DT** **** home treatments need to be used for at least 2-4 weeks to be effective**	1- Cavity varnish – applied on the exposed dentine , provides immediate relief but it's effect is temporary for few hours or days only 2- Restorative materials [GIC, RMGIC etc] 3- Bioglass – can promote remineralization of DT 4- Iontophoresis: a device that uses low electrical current – causes the formation of reparative dentine + produces parasthesia + causes precipitation of calcium fluoride → blocks the DT 5- Laser : can physically occlude the DT + cause coagulation and protein precipitation inside the DT 6- Periodontal surgery to cover gingival recession 7- RCT

DH prevention

For Patient	For clinician
1- Avoid aggressive tooth brushing with hard bristle tooth brush and abrasive tooth paste **2-** Avoid brushing immediately after ingesting acidic foods 3- Avoid picking at the gum line with toothpicks **4-** Avoid excessive flossing and inappropriate use of interdental cleaning aids	1- Avoid over instrumentation of root surfaces during SRP 2- Avoid over polishing dentine during satin removal 3- Avoid violating the biological width while placing restorations → this can lead to recession **4-** Avoid burning the gingival tissues during bleaching

Halitosis

- **Genuine halitosis :** when breath malodor really exists
- **Pseudo halitosis :** there is no breath malodor but the pt is convinced that they have it.
- **Halitophobia:** if the pt is still convinced that they have breath malodor even after the treatment of genuine halitosis or pseudo halitosis [considered a psychiatric disorder]

- Halitosis has no gender predominance [women have it more because they seek treatment for it more than men]
- There is no association between increased age and halitosis

Malodor is caused by the release of **volatile organic compounds** [volatile sulfur compounds]

Genuine halitosis is either physiological or pathological:

A. **Physiological** : morning bad breath, after eating onions and garlic or spices, medications like anti-depressants and diuretics – doesn't reflect a pathology

B. **Pathological:** persistent breath malodor that reflects a pathology

1- **Intra oral [90% of the cases] :** caused by an increase in bacterial load or the substrates for bacteria**, causes :**

- The rough surface of the tongue acts as niches for bacteria + desqumated cells and food remnants [food remnants are puterified by bacteria and release volatile organic compounds causing malodor]
- Deep pockets/ NUG leisons / pericoronitis / deep carious lesions will also act as niches for bacteria to release Volatile Sulphur compounds
- Dry mouth [xerostomia will increase plaque and tongue coating]

2- **Extra oral :** caused by increase in certain metabolites in blood that escape through the alveoli of the lungs during breathing , can be respiratory or non respiratory:

A. Respiratory :

B. Non – respiratory :

- **Metabolic**
- **Hepatic**
- **Renal**

GIT problems do not cause halitosis

Transient halitosis can happen during menstrual cycle

Ear nose throat problems [pharyngitis , tonsillitis etc]	Rotten eggs smell
Diabetic keto acidosis	Rotten apple smell
Liver problems	Fecal smell
Kidney problems	Fishy smell

Q: how do you diagnose halitosis? IMP

1- **Medical history** [ask about medical problems, any current medications, when did the problem start etc ..]
2- **Clinical examination** [look for carious lesions, areas of food impaction , pockets, tongue coating, signs of xerostomia , if there is pericoronitis, tonsillitis]
3- **Measure halitosis:**
   A. **organoleptic measurements** : using two Odor Judges **without gloves** – subjective method Two days before the measurements pt has to avoid spicy food, garlic, and onions. The use of any fragrance, shampoo, body lotion, tooth paste, or mouth rinse; smoking; and the consumption of alcohol or coffee are **prohibited 12 hours before the assessment .** The odor judge will sniff **[oral cavity odor , nasal breath odor , breath odor , after allowing saliva on the wrist to dry]** + inspect posterior tongue and pharynx and give a score:

0 = no odor present	3 = moderate odor
1 = barely noticeable odor	4 = strong offensive odor
2 = slight but clearly noticeable odor	5 = extremely foul odor.

   B. **sulfide monitoring:** using portable volatile sulfur monitor [Pt breathes into a tube connected to a machine] – can only detect sulfur compounds
   C. **gas chromatography:** can analyze air, saliva, GCF – can detect any compound
   D. **microbial testing (cultures, smears, enzyme assays)**

Tongue coating indicies

Miyazaki tongue coating index		Winkel tongue coating index	
Score 0 = none visible **score 1 = less than one-third of the tongue is covered** **score 2 = less than two-thirds** **score 3 = more than two-thirds**		Divide the dorsum of the tongue is into six areas, [three in the posterior and three in the anterior part of the tongue] The tongue coating in each sextant is scored as : 0 = no coating 1 = light coating 2 = severe coating.	

Q: how id halitosis treated ? IMP

1- **identify the cause**
2- **classify pt tx need [TN]**

Treatment needs [TN]

TN 1	Explanation about halitosis + OHI Applicable to all cases [from TN 2 to TN 5]
TN 2	Oral prophylaxis , treatment of oral diseases and periodontal disease
TN 3	Referral to a physician / medical specialist
TN4	Explain examination data + further professional instruction , education and reassurance
TN5	Referral to a psychologist , psychiatrist

- Physiological halitosis → TN1
- Intra oral pathological halitosis → TN 1 + TN2
- Extra oral pathological halitosis → TN3
- Pseudo halitosis → TN 1 and TN 4
- Halitophobia → TN 5

3- Treat all dental pathologies :

A. **Mechanical reduction of bacteria and their substrates –**
SRP + CHX irrigation **+** tongue cleaning with tongue scraper – best to clean as far back as possible because the coating is heavier posteriorly

B. Chemical reduction [CHX mouthwash, essential oils (listerene) etc]

C. Conversion of volatile sulfur compounds [by chewing gums, tooth pastes etc]

D. Masking the malodor [mint containing lozenges]

The pt can self examine the improvement of halitosis by:

1- Smelling a metallic or a plastic spoon after scrapping the back of the tongue
2- Smelling the tooth pick after inserting it interdentally
3- Spitting in a cup and allowing it to dry then smelling it
4- Licking the wrist and allowing it to dry then smelling it [**evaluates the volatiles originating from the saliva and anterior part of the tongue]**
**** breathing into the hands and then smelling is not effective because the nose gets used to the smell of skin or hand soaps**

Food impaction

Food impaction = forceful wedging of food into the periodontium by occlusal forces

Vertical impaction	Horizontal impaction
Impaction from occlusal direction due to action of opposing tooth. Causes: **1-** Open contact between teeth **[pt will tell you they <u>need to use a tooth pick after every meal</u>]** **2-** Irregular or level difference between adjacent marginal ridges. **[This causes the food to remain on the occlusal surface. Patient complains that he has to either <u>gargle after meals or has to brush</u>. Or that <u>guava, pomegranate seeds getting stuck.</u>]** **3-** Plunger cusps	Impaction due to periodontal destruction periodontal destruction [with or without recession] causes food to get stuck → enlargement of gingival embrasure + further food entrapment due to pressure from tongue lip and cheek

Factors Causing Food Impaction :

- Class I: Occlusal wear
- Class II: Loss of proximal contact
- Class III: Extrusion beyond the occlusal plane
- Class IV: Congenital morphological abnormality
- Class V: Improperly constructed restoration

Q: why should you treat food impaction?

When food is impacted the pt will have a constant urge to dig and remove it → gingival inflammation with bleeding and foul taste → gingival recession and can lead to periodontal abscess and alveolar bone destruction

Food impaction prevention & management

- **Periodontal Treatment: SRP +** interproximal brushing + curettage
- **Occlusal adjustment** : Round the cusp tips of plunger cusps + adjust any extruded teeth that cause discrepancy in the level of marginal ridges . [if mild can be done by simple grinding, if severe need restorations to adjust]
- **Restoring an ideal Contact**

Periodontal surgery – general principles

Phase I therapy:

1- SRP
2- Reinforce OH + antimicrobial agents [ex: CHX]
3- Adjust plaque retention areas and modify risk factors [smoking and better glycemic control]

After phase I therapy → inflammation reduces → pockets become **inactive and reduces in depth**

Ex: A active 5 mm pocket after non surgical perio therapy should heal and become non active [no bleeding , no puss] but it can stay as 5mm or gain attachment to become 3mm or 2mm.

Pockets:

A. **Active =** bleeding + exudation + ongoing periodontal destruction and bone loss + pain
B. **Inactive =** no bleeding or exudation + no destruction and the pocket **heals by long JE**

Q: what is the reason for pocket reduction after non surgical perio therapy?

Either the gingiva was inflamed and edamatous and after SRP the inflammation reduces and the gingiva shrinks → reduction in pocket depth OR the gingiva was not inflamed by the gingival attachment heals by forming a long JE. [very weak attachment and can easily be destroyed again to form a pocket again].

Non surgical perio therapy → healing by forming long JE

Surgical therapy → regeneration of lost tissues and healing by formation of a healthy sulcus

Q: what is the ideal outcome of treating periodontal pockets? generation of the lost periodontal structures [bone + cementum + PDL] – this can only be achieved by surgery .

NOTE: surgery will produce similar results to non surgical therapy after 3-5 years BUT **surgical therapy will result in greater pocket depth reduction at initially deeper pocket that at more than 4 mm**

Q: why does periodontal surgery cause more pocket depth reduction? Because it increases accessibility to root surface and allows complete elimination of plaque, calculus and altered cementum.

If the pocket did not heal after non surgical therapy → indication for periodontal surgery

For all pts with periodontitis you perform phase I therapy and then decide based on the results if you need to do surgery or not.

Q: why is it important to perform phase I therapy before periodontal surgery ? because it might eliminate some lesions completely [reduce the number of sites that need surgery] + it will reduce inflammation and make the tissues more firm and consistent allowing more accurate surgery

Reasons for doing periodontal surgery:

1- Improve access to root surfaces in the treatment of periodontitis to remove diseased tissues
2- pocket elimination/ pocket depth reduction
3- regenerative techniques: guided tissue regeneration/ defect fill/ biochemical conditioning/ growth factors
4- removal gingival enlargements

5- exploration of defects/ detection of cracks
6- Crown lengthening
7- Improvement of esthetics → periodontal plastic surgery
8- Correction of bony defects (alveoloplasty)

Indications	Contraindications
1- irregular bony contours, deep craters, and other defects usually require surgical approach. 2- Pockets on teeth where you cannot completely remove irritants with non surgical approach (molar and premolar areas). 3- Furcation involvement of grade II or III [to ensures the removal of irritants + do root resection or hemisection] 4- Intrabony pockets on distal areas of last molars are usually unresponsive to nonsurgical methods. [they are usually formed after the extractions of 3rd molars] 5- Persistent inflammation in moderate to deep pockets shallow pockets with persistent inflammation → indicate mucogingival problem [frenal pull]	1- Severely medically compromised (poorly controlled diabetes, bleeding disorders, people taking anticoagulants) 2- Poor response to previous surgery. 3- Pt emotional state [they are not ready for surgery]

Periodontal surgery is either:

1. **Pocket therapy** [to gain access for removal of irritants like calculus and altered cementum from root surf and to eliminate or reduce the pocket]

A. Resective [papillectomy, gingivectomy, apically displaced flap, displaced flap with or without osseous resection]
B. Regenerative [flaps with grafts or membranes]

2. Correction of anatomical defects [mucogingival defects]

Those surgeries do not treat disease but alter the gingival and mucosal tissues to correct defects that may predispose to disease

1. **Plastic surgery** to **widen attached gingiva** (free gingival grafts)
2. **Esthetic surgery** (root coverage, recreation of gingival papilla)
3. Preprosthetic surgery [crown lengthening, ridge augmentation, and vestibular deepening]
4. Placement of dental implants

General principles of periodontal surgery

1- **Re evaluate after phase I therapy :** re probe deep pockets and re examine all findings that previously indicated the need for periodontal surgery – persistence of such findings indicates the need for periodontal surgery [ex: pockets that did not heal]
2- **Premedication:**
A. **ABX :** antibiotics are given before periodontal surgery and continued for **4 to 7 days after surgery** → reduces postoperative complications + pain and swelling.
ABX will enhance bone grafting and attachment gain [indicated for bone grafting procedures and mucogingival surgeries] – ABX are not indicated for gingivectomy, crown lengthening, flap without bone exposure]

**** if you are exposing bone or doing a surgery to gain attachment → ABX will give benefit, otherwise don't give ABX"**

B. NSAIDs [ibuprofen] 1 hour before surgery to reduce post op pain
C. One oral rinse with 0.12 % CHX [peridex, curasept, periogard] to reduce post op infection

3- **Smoking :** pt should quit or stop smoking one week before surgery and **3-4 weeks after surgery** [total of one month]
4- **Informed consent**

Procedure:

1- **Tissue management :** operate gently and carefully [roughness produces excessive tissue injury → **post op discomfort + delayed healing]**
2- **Observe the pt at all times :** pay attention to facial reactions, pallor, sweating etc
3- **Make sure the instruments are sharp :** dull instruments will result in unnecessary trauma because of poor cutting and excessive force used
4- **Scaling + root planning :** all root surfaces must be cleaned properly
5- **Hemostasis :** Surgery can produce profuse bleeding, especially during the initial incisions and flap reflection - After **removal of granulation tissue, bleeding disappears or is reduced.**
Intraoperative bleeding → managed with aspiration or **pressure with a cold moist gauze**
LA with a vasoconstrictor can control minor bleeding from the periodontal flap - If a vessel is lacerated, a suture around the bleeding end.
CAUTION: using LA + vasoconstrictors to control bleeding should not be used towards the end of the surgery because the pt will have bleeding when they go home and after suturing the flap [because the effect of the vasoconstrictor goes away]
   - For **slow, constant blood flow and oozing** → use hemostatic agents [oxidized cellulose, collagen, absorbable collagen sponges]
6- Apply periodontal dressing [periodontal pack] – Packs have no healing properties but they assist healing by protecting the tissue from infection and trauma during healing
Periodontal packs are either :

A. ZOE packs
B. **Non eugenol packs** [ex: Coe-pak] contains **lorithidol** [fungicide] in one tube and **chlorothymol** [bacteriostatic agent] in another tube.
C. **Cyanoacrylate [periacryl] :** easy to apply since it is a liquid and provides rapid hemostasis even in the presence of liquid]

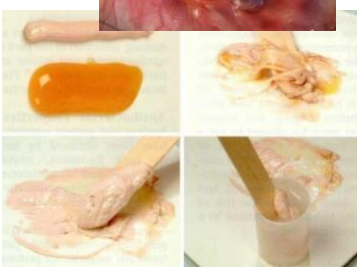

Q: how do you mix coe-pack ? mix equal lengths of paste until you get a uniform color [A capsule of tetracycline powder can be added at this time] → place the mix in a cup of water at room temperature. In 2 to 3 minutes the paste can be handled and molded.

Q: how can you make coe pack set faster? By adding zinc oxide to the accelerator (pink paste) before spatulating

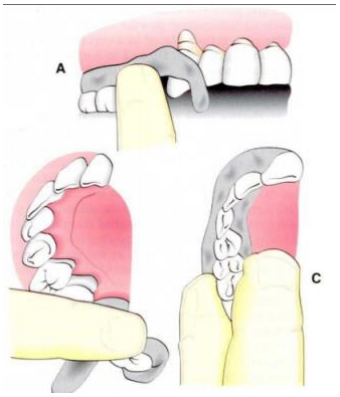

Q: how do you apply coe pack ? apply Vaseline on your gloves before manipulating the dressing then apply coe pack half on the tooth and half on the gingiva both buccaly and lingually and then press firmly to make sure they join interproximally [once the dressing sets it will become retentive]

Check occlusion [coe pack should not interfere with occlusion]

Q: why is the coe pack placed palatally even if no incisions are placed there?
To gain interdental retension with the buccal peice

Post-operative complications management

1- **Persistent bleeding after surgery:**
Management : Remove the pack → locate the bleeding points → stop the bleeding with pressure and a moist gauz. if the bleeding persists → use electrocautery . if the bleeding persists → remove the sutures and check the site for any remaining granulation tissue then re pack again.

2- **Swelling:** it is normal to have a localized inflammatory reaction to the surgery in the first 2 days [painless swelling of the cheek + Lymph node enlargement and slightly elevated temperature]
It generally subsides by the **fourth postoperative day**
If swelling persists or becomes worse and painful → **amoxicillin (500 mg) every 8 hours for I week, + moist heat applications over the area.**

3- **Sensitivity to percussion:** caused by extension of inflammation into the periodontal ligament or excess periodontal dressing that interferes with occlusion.
Management : Remove the pack → check for localized areas of infection or irritation → clean those areas and drain them if necessary + remove any calculus that you might have missed + relieve the occlusion
If the cause if excess dressing → remove the excess

4- **Feeling of weakness :** Patients report a **"washed-out" weakened feeling 24 hours after surgery.**
Caused by **transient bacteraemia** induced by the procedure.
Should be prevented by premedication with **CHX oral rinse and amoxicillin (500 mg) every 8 hours, beginning 24 hours before the procedure and continuing for 5 days postoperatively.**

Perio surgery instruments

1- **Periodontal knives [gingivectomy knives] –** Kirkland knives are typically used for gingivectomy [**kidney shaped knives** with blades on it's entire periphery **]**

2- Interdental Knives [Orban knife and the Merrifield knife] : **spear-shaped** knives with cutting edges on both sides of the blade

3- **Prichard curettes :** larger an heavier curettes to remove calculus, granulation tissue etc.
Surgical curettes can't be used for phase I therapy because they are very bulky and need a flap reflected.

4- **Periosteal elevators:** Woodson elevators to reflect the flap



5- **Surgical chisels :** Ochsenbein chisels - for bone removal and contouring.

6- **Scissors:** Goldman fox scissors - used in areas where you don't want to expose bone - to remove tabs of tissue during gingivectomy, to trim the margins of flaps

Q: why should you only use scissors to cut muscle attachments and not blades? Because blades are sharp and can easily expose bone

Vertical bone loss → resective bone surgery

2-3 wall bone defect → regenerative bone surgery

Vertical bone loss / defect will not hold the graft material properly + the pt cannot clean this area properly [there will always be calculus at the base of the pocket] → continued bone loss → you need to change it to a horizontal bone loss by doing **resective bone surgery**

Periodontal surgery – gingivectomy / gingivoplasty

Gingivectomy = excision of gingiva by removing the pocket wall, it provides access and visibility to remove calculus + smoothen root surface

- it is a **pocket reduction surgery** limited **only to gingival tissues** and **does not involve underlying bone**
- By removing the pocket wall a favorable environment is created for gingival healing and restoration of the normal gingival contours
- After gingivectomy there wont be any pocket depth

Indications	Contraindications
• Elimination of gingival enlargements • Elimination of suprabony periodontal abscess	• If you need to do **bone surgery or examination of bone shape** • If the **bottom of the pocket is apical to the mucogingival junction**

Drug induced enlargement = ask the physician if the drug can be changed + gingivectomy

Inflammatory enlargement = reinforce OH + SRP [if not responsive → gingivectomy]

Leukemia enlargement = YOU CAN'T DO GINGIVECTOMY , because you can't control the bleeding that results from gingivectomy [consult physician]

Gingivectomy can be done by: scalpels, gingivectomy knifes, laser

Procedure:

1- **LA** : infiltration directly into the tissues [sometimes you give infiltration into the sulcus] but rarely needs a block.

2- Mark the deepest points of the pocket using a **pocket marker** [similar to a perio probe but has one straight end that is placed in the pocket and one end that is **bent at 90 ° inward** to cause bleeding points at the depth of the pocket] – **3 -4 marks are made for each tooth**

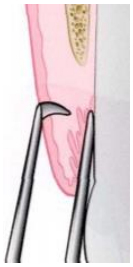

3- **Incision :**
Periodontal knifes [Kirkland knives] are used for incisions facially and lingually
Kirkland knives are safer + they have their own angulation that creates and incision at 45° giving the scalloped knife edge contour of the gingiva
Orban knives or **blade #12** or **# 15** are used for incisions interdentally
Incision starts 1-2 mm apical to the bleeding points + it's directed **coronally to a point between the base of the pocket and the crest of the bone**. It should be **as close as possible to the bone without exposing it**
Incision should be beveled at 45 ° to create the normal contour
The incision in gingivectomy is external bevel incision

4- **Remove gingival tissues , calculus granulation tissue and tissue tags**

5- Use coarse diamond burs , Gracey curettes or the side of the Kirkland knife for gingivoplasty :

[taper the gingival margin and create the scalloped outline + thin the attached gingiva and create vertical interdental grooves]

6- Apply co pack for 2 weeks [to reduce post op discomfort and prevent gingival tissue regrowth
7- Review after 1 week to remove co pack and see healing

Gingivectomy should ALWAYS be followed by gingivoplasty , but gingivoplasty can be done alone [ex: in cases of ANUG]

Gingivoplasty : Reshaping the gingival tissue to re create normal gingival contours in the absence of pockets.

Can be done with scalpels, periodontal knives, diamond burs, electrodes.

In gingivoplasty you:

1- Taper the gingival margin
2- Create the scalloped gingival margin
3- Thin the attached gingiva
4- Create vertical interdental grooves + shape the interdental papilla

Traditional gingivectomy : external bevel incision at 45 ° starting slightly apical to the bleeding points.

If the tissue is very hyperplastic you can do an internal bevel incision and then suture

Q: how does the tissue heal after gingivectomy? A blood clot forms → granulation tissue → fibroblasts make the tissue grow coronally

Complete epithelial repair takes about 1 month - Complete repair of the connective tissue takes about 7 weeks

Electro surgery :

- Perfect if you want to remove small gingival proliferations, expose subgingival caries, expose preparation margins etc.

CAUTION while using Electro surgery :

- Avoid touching **bone, teeth and metallic restorations**
- Avoid electrosurgery around implants
- **Contraindicated in heart pacemaker patients**
- **Contraindicated in radiation therapy and acutely immuno-compromised patients**
- Do not use near flammable vapors/liquids
- Do not use with N2O or O2
- **Do not retract tissues with metal instruments**
- Avoid prolonged tissue contact
- Have good ventilation/ suction (non-metal)

Electrosurgery :

You clean the surgical site with 0.2% CHX on a cotton pellet

You remove tissue from the INACTIVE probe using gauze with alcohol

Only bi polar electrosurgery units can be safely used with pts that have pacemakers

Advantage	Disadvantage
coagulation as it cuts + sterilizes the tissue	- Cannot be used in pts with pace makers - If accidentally touches root causes cementum burns - If accidently touches bone can cause necrosis + gingival recession - Metal restorations can act as conductors

Periodontal surgery – periodontal flaps

Most widely used periodontal surgery .

Periodontal flap	Gingivectomy
Location of the incision depends of the purpose of the surgery	Location of the incision is predetermined by the pocket depth
Internal bevel incision	**External bevel incision**
The direction of the incision is APICAL	The direction of the incision is CORONAL
You can choose to expose bone or keep a layer of periosteum over it.	Bone is not exposed

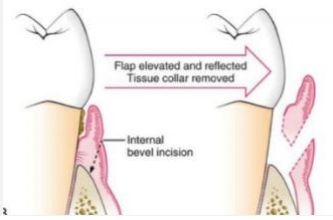

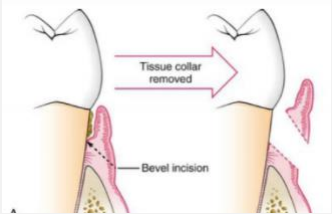

Classification of flaps :

1- **Based on bone exposure after reflection:**
   A. **Full thickness flap [mucoperiosteal flap]:** you reflect all of the soft tissue and periosteum to **expose the bone.**
   Needed in: resective or regenerative bone surgery

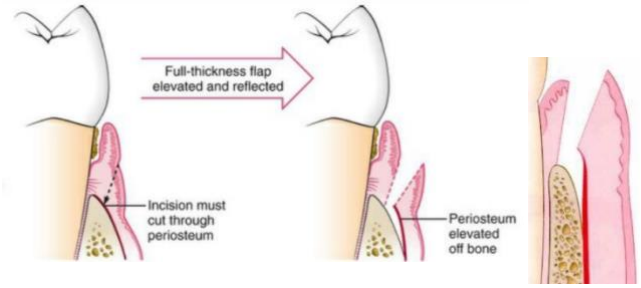

   B. **Partial thickness flap [mucosal / split thickness flap]:** includes only epithelium and a layer of underlying CT – **DOES NOT EXPOSE BONE**
   Needed in : apically displaced flaps and when you don't want to expose bone.

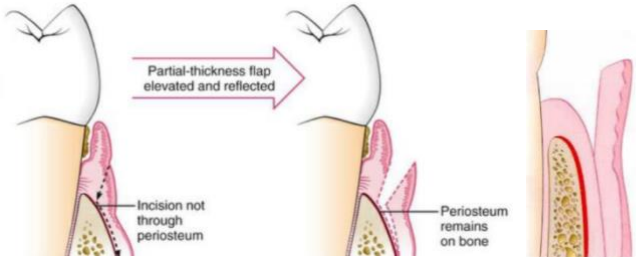

2- **Based on placement of the flap after surgery :**

A. **Undisplaced flap** : the flap returns to it's original position

B. **Displaced flap:** flap can be placed apically , coronally , laterally etc

3- **Based on management of the papilla:**

A. **Conventional :** the incision is placed at the top of each interdental papilla to split it to a buccal half and a palatal / lingual half [Ex: modified Widman flap, apically displaced flaps]

B. **Papilla preservation flap:** incorporates the entire papilla in one of the flaps [used in aesthetic zones and when there are bone defects that need to be treated by regenerative materials , this way the incision and sutures will be away from the defect]

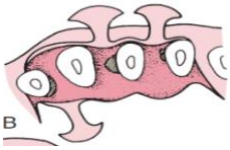

Both full thickness and partial thickness flaps can be displaced but the **attached gingiva must be totally separated from the underlying bone** and you have to **reflect till the alveolar mucosa** to get the elasticity to move the flap

If the MGJ is close to the gingiva → do the incision at the gingival margin to preserve as much keratinized tissue as possible

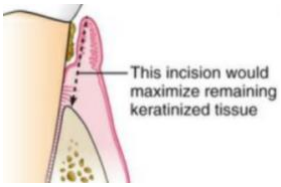

Incisions :

Horizontal incisions:

A. **Internal bevel incision:** Starts from the designated area on the gingiva & directed to an area at or near the crest of bone
Used to: remove the pocket lining + Produce sharp, thin flap margins
Can be marginal or submarginal

B. **Crevicular incision :** From the bottom of the pocket to the crest/ margin of the bone

C. **Interdental incision :** to remove the V –shaped wedge between the 1st and 2nd incision that contains granulation area and inflamed tissue

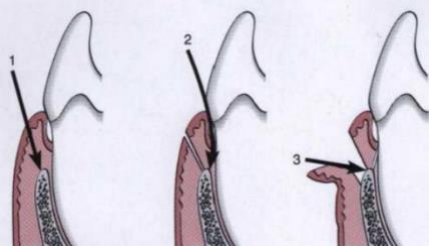

Vertical incisions:

Needed in : small flaps [fixing a defect on one tooth only] or when you need to displace a flap

- **Must extend beyond MG Line to the alveolar mucosa**
- Usually on facial - avoid lingual or palatal
- Made at the line angles of a tooth to include papilla in flap or avoid it completely
- Not made in the center of interdental papilla or radicular surface of tooth

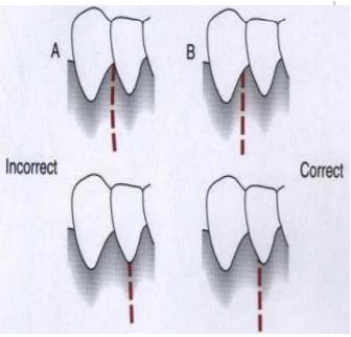

Indications of periodontal flaps:

1- Pocket depth did not reduce after instrumentation → flap to access for instrumentation
2- Excessive drug induced enlargements → gingival resection
3- Bone defects regeneration or resection
4- Periodontal regeneration

Periodontal flap	Notes
Modified Widman	Exposes roots for cleaning **DOES NOT ELIMINATE POCKET**
Un displaced flap	Exposes the root for cleaning eliminates the pocket **
Apically displaced flap	**Exposes the root and furcation areas for cleaning** Eliminates the pocket ** **Preserves or increases the width of attached gingiva** Creates recession**

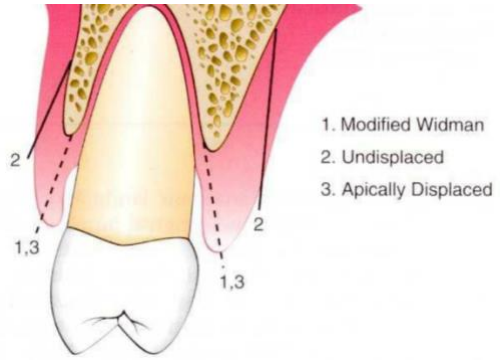

NOTE: one wall bony defect can't be fixed by regeneration procedures → you need to resect it to form a horizontal bone loss – only 2 or 3 wall bony defects can benefit from regenerative procedures

- If the gingiva is very thin → do sulcular incision
- If the gingival margin is inflamed → incision should be 1 mm apical to eliminate this area of inflammation

Modified Widman flap procedure:

Internal bevel incision 0.5 – 1 mm below the gingival margin [follow the scalloped contour → reflect the gingiva and remove granulation tissue + tissue tags [with curettes first then diamond burs] → reposition the flap and suture [horizontal mattress suture is preferred because it does not pass over the papilla and prevents recession]

NO dressing is needed – prescribe CHX mouth wash 0.2 % twice daily for 1 week – NO BRUSHING OR FLOSSING IN THE AREA OF SURGERY

Un displaced flap procedure: only done when you have **enough keratinized gingiva** – where you place your internal bevel incision **depends on the depth of the pocket** [you must place it half way through the pocket – if the pocket is 6 mm the incision is placed 3 mm away from gingival margin]

ALL PERIODONTAL FLAP EVENTUALLY CAUSE GINGIVAL RECESSION+ BONE RESOPRTION

Q: How is modified Widman flap different from Undisplaced flap? In undisplaced flap the soft tissue pocket wall is removed with the initial incision [may be considered an "internal bevel gingivectomy ']
The Undisplaced flap and the gingivectomy are the two techniques that surgically remove the pocket wall

Q: why is it difficult to clean pockets on the distal aspect of the last molar? What might be a possible solution to ensure adequate scaling in that region?

1- Poor accessibility + presence of maxillary tuberosity and prominent retromolar pads
2- Deep vertical defects might be due to incomplete repair after extraction of impacted 3rd molar

Possible solution: distal molar surgery

Distal molar surgery to gain access and correct defects on the distal of the last molars

Pre requisites:

Maxilla : Long distal tuberosity with abundant attached gingiva

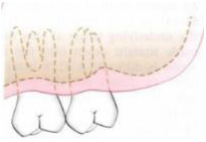

Mandible: abundant attached gingiva and distal space

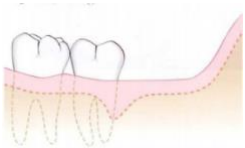

Two parallel incisions, beginning at the **distal of the tooth** and **extending to the mucogingival junction** [should NOT include the ucosa]distal to the tuberosity or retromolar pad then a **transversal incision** is **made at the distal end of the two parallel incisions. Or wedge shaped incision following the greatest attached gingiva and underlying bone**

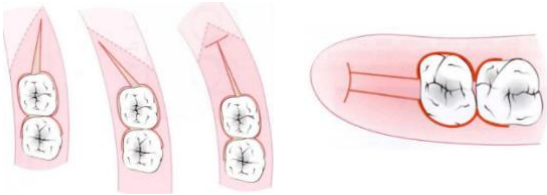

Papillectomy

Indicated if you **only have proximal defect / pocket with no buccal or lingual bone loss** → straight incision to remove the interdental papilla and gain access to clean the root surfaces

No sutures are needed – Just apply coe pak for one week

NOTE: since all periodontal flaps result in recession they should be avoided anteriorly unless the pt has a low smile line and if you are placing regenerative material [do papilla preservation flaps]

Periodontal surgery- Guided tissue regeneration

Melcher's hypothesis [population theory] : the type of cell that repopulates on the root surface will determine the type of attachment that forms.

After SRP healing can be :

A. If epithelial cells migrate to the area → healing by long JE
B. If CT cells migrate to the area → healing by CT attachment + root resorption
C. If bone cells migrate to the area → healing by ankylosis + root resorption

Guided tissue regeneration: after SRP a barrier is placed to prevent the migration of epithelial and CT cells and allow only PDL cells to migrate and regenerate the attachment to root surface [this procedure may be combined with bone grafts]

- The membrane will only act as a space holder , the defect is filled by the pt's own cells.
- **Best prognosis is for 3 wall interdental bony defects and mandibular class 2 furcations**

Membranes used in GTR:

A. Non resorbable [GORTEX membrane] = require a second surgery for removal – the second time you access the defect you can cause 0.5- 0.8 mm CAL

B. Resorbable = no need for second surgery

- **Enamel matrix derivative – EMD [Emdogain] :** a gel that is placed into the defect and can be stimulate periodontal hard and soft tissues to regenerate **– better results than GTR** https://www.youtube.com/watch?v=_gn-OBzkoEU
- Root surface condition can be done with tetracycline or citric acid [no longer used]
- Newest approach is adding growth factors (PDGF) instead of EMD

GTR complications:

1- Insufficient primary wound closure
2- Membrane exposure and bacterial contamination
   A. If resorbable membrane gets exposed → you lose the membrane + there will be no gain in attachment - Sometimes the inflammation and bacterial contamination can reach into the pocket and cause an abscess
   B. If a non resorbable membrane is exposed → bacterial adhesion + un esthetic appearanc

Bone grafting with GTR :

BONE GRAFT	NOTES
AUTOGRAFT	From the same pt – no rejection Second surgery is needed for bone harvesting [risk of infection, morbidity etc] You can get limited amount only Bone is usually harvested from [iliac crest, chin, tibia]
ALLOGRAFT	From another individual Can be cadaver or living donor Can cause immunological rejections + has risk of transmitting hepatitis and HIV
XENOGRAFT	From animals – Bovine derived Xenograft [BDX]
ALLOPLASTIC MATERIAL	Synthetic material – hydroxy apatite better if it's mixed with centrifuged blood from the pt – but blood is difficult to obtain so we mix it with pt's saliva

All bone grafts must be covered by a **resorbable membrane** to :

1- Provide better infection control
2- Prevent migration of tissues

- The most common mistake in bone grafting is over packing the bone into the defect [you need to allow spacing b/w the particles to allow regeneration]
- **Combining autograft + xenografts** provides better results in defect regeneration [this will prevent the shrinkage of autograft and maintain it's volume]

Bone that forms from bone grafts need 6-8 months to become mature bone – don't load the tooth with a restoration before 6 months .

Least to highest success :

1- Autograft alone + membrane [graft is not stable and will shrink]
2- Autograft + alloplast + membrane [still undergoes shrinkage but better results]
3- Autograft + xeno graft + membrane [best results because the graft remains stable without shrinkage]
4- EMD + BDX + resorbable membrane [EMD will regenerate the PDL , BDX will regenerate the bone]

Mucogingival surgeries and periodontal esthetics

Recession causes:

1- Anatomic conditions [including lack of attached gingiva, inadequate thickness of the alveolar bone plate and root prominences]
2- Muscular inserts near the gingival margin [high frenal attachement]
3- Poor tooth alignment [crowding, because eit causes some teeth to be pushed out of the alveolar bone]
4- Acquired pathological conditions [periodontitis]
5- Iatrogenic factors [restorations invading the biological space]
6- Mechanical trauma, including tooth brushing

Generalized recession can be caused by :

1- If ortho tx pushes the teeth beyond the alveolar bone to increase the width of the arch → generalized recession
2- Anatomical defects [if the labial bone is thin and only covered by gingiva + traumatic heavy tooth brushing → recession]
3- Inheriting small jaw from one parent and large teeth from another parent will cause generalized recession [also fenestrations and crowding]

Localized recession can be caused by : high frenal attachments → during speech and mastication the frenum will pull the gingival margin down causing recession and inflammation due to bacterial accumulation

Q: can traumatic tooth brushing cause recession? Only if there is a problem in the underlying bone [thin alveolar bony plate , fenestrations, dehiscence etc]

Recession classification [miller's classification]

Class I	**Recession that does not extend to the MGJ , no bone or ST loss in the interdental area**	
Class II	**Recession extends to or beyond MGJ , no bone or ST loss in interdental area**	
Class III	**Recession extends to or beyond the MGJ , there is bone and ST loss in the interdental area or malpositioning of teeth**	

Class IV	**Recession extends to or beyond MGJ, there is severe bone and ST loss interdentally or severe tooth mal positioning**

Cairo classification	
RT1	Buccal CAL without interdental CAL
RT2	Buccal CAL equal or more than interdental CAL
RT3	Buccal CAL is less than interdental CAL [interdental CAL > buccal CAL]

Miller class 3 and 4 / RT 2 and RT3 → difficult to treat by perio surgery

Periodontal biotypes:

Biotype 1 = thick [square teeth + wide roots + thick alveolar bone and thick gingiva]

A. Thick flat : square teeth + large interproximal contact areas
B. Thick scalloped : oval teeth + small interproximal contact areas

Biotype 2= thin [triangular shaped teeth with thin roots and alveolar bone and thin gingiva] – **fenestrations and dehiscence are common**

Q: when is recession indicated for surgical correction?

1- Recession is increasing
2- Persistent inflammation
3- Dental hypersensitivity
4- Esthetic concerns
5- Root caries
6- Young pt with recession

Surgical techniques that increase attached gingiva:

1- **Augmenting gingiva apical to the recession [root is not covered]**
   Indications:
   - **A.** Multiple recessions , wide recessions, miller's class III [recessions that are hard to cover → you stop the progression of the recession by increasing attached gingiva apical to the recession]
   - **B.** Thin , convex roots and thin interdental papilla [the flap gets it's blood supply from the interdental papilla so if you do coronal augmentation the flap will necrotize because the interdental papilla is thin]

2- **Augmenting gingiva coronal to the recession [root coverage]**
   Indications: to cover root surfaces and improve esthetics

Both techniques will enhance oral hygiene but only coronal augmentation will improve esthetics and cover the root.

Management of gingival recessions [tx options] :

1- **Free ST grafts [a graft is taken from the pt's palate and transplanted somewhere else]**
   A. **Free gingival graft [epithelized graft] :** the graft has outer epithelial layer and an underneath layer of CT.
   B. Sub epithelial CT graft : has only CT no epithelial layer
2- **Pedicle grafts:** the graft is attached to the alveolar mucosa [not taken from the palate]
   A. Rotational flaps : lateral sliding flap , double papilla flap, oblique rotated flap
   **** lateral sliding graft =** in case of single recession – the neighboring keratinized tissue slides over the recession
   B. **Advanced flaps:** semilunar flaps, coronally repositioned flaps

   ** coronally repositioned flaps are used to cover multiple recessions

3- **CT graft + coronally advanced flap**
4- **Acellular dermal matrix [obtained from the skin of the donor]**

Lateral sliding flap

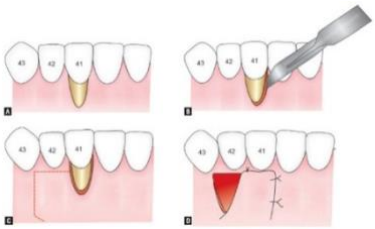

- **Indication:** isolated recession [long recession reaching MGJ]
- **Requirements:** enough attached gingiva on both sides or one side
- The operative field is covered with aluminum foil and then perio pack

Watch the video: Periodontal Surgery –Lateral sliding flapLength 8.11 minutes Dr Soukoulis and Dr Kardachi

Coronally repositioned flap

- **Indication:** to cover isolated or multiple gingival recessions
- **Requirements :**

A. intact interdental papilla [no interdental papilla recession] + no interdental CAL or bone loss
B. enough keratinized gingiva apical to the recession [if there is not enough keratinized tissue apically → do a graft to increase keratinized tissue then reposition it coronally]

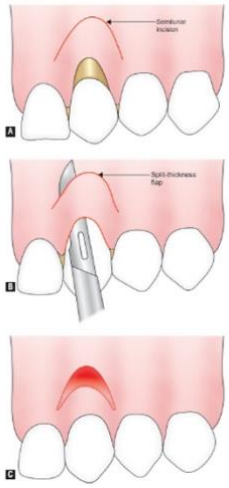

Semilunar flap

- **Indication:** isolated recession that is **only 2-3 mm**
- **Requirements:**
  lack of tissue inflammation
  minimal pocket depth labially
  intact interdental papilla + enough keratinized tissue below the recession
- **Advantages:**
  1- No vestibular depth like in coronally repositioned flap
  2- No esthetic compromise on interdental papilla
  3- No sutures needed

Disadvantages :

1- Cannot treat large areas of recessions
2- A FGG has to be placed if there is underlying dehiscence or fenestration

Coronally repositioned flap creates vestibular shortening but in semi lunar flaps there wont be any vestibular shortening

Pt with marginal gingivitis and pocket depth more than 1mm → you cannot do semilunar flap

Q: what happens if you do a semi lunar flap on a tooth with deep pocket ? when you move the tissue coronally you will expose the tissue apically → recession and failure of the flap

Free gingival graft: epithelized graft

By increasing the width of the keratinized gingiva using FGG → pt's oral hygiene improves + you stop further recession

Indications :

A. To cover exposed roots
B. to increase width of keratinized gingiva
C. loss of interdental papilla
D. recessions [miller's class III]

Q: how can you replicate the pattern on the recipient site [you can you know how much tissue you need to take from the palate]? Using a piece of sterilized aluminum foil , cut in the desired shape of the graft needed then placed on the palate as a template

Q: where do you get a palatal FGG ? in the area between the premolars and molars [1-2 mm away from the gingival margin – graft thickness should be 1-1.5 mm]

Complete healing after perio surgery takes 6 months – but a crown can be placed after 3 months

Q: how can the open wound in the palate be covered ?

A. sutures then perio pack

B. for very large wounds – an impression is taken before the surgery to prepare an acrylic stent with retentive arms that will be worn for 1 – 1.5 weeks after surgery until epithelization occurs

CT graft surgeries are mainly used for root coverage but FGG can be used for root coverage and to increase the width of keratinized gingiva.

Subepithelial CT graft **[CT only , but has a small epithelial band] :** A flap is made on the palate to obtain the CT graft under the epithelium , then the epithelium is reapproximated and sutured by resorbable sutures

CT grafts have double blood supply : from recipient bed + from covering flap

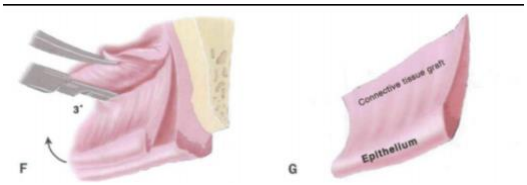

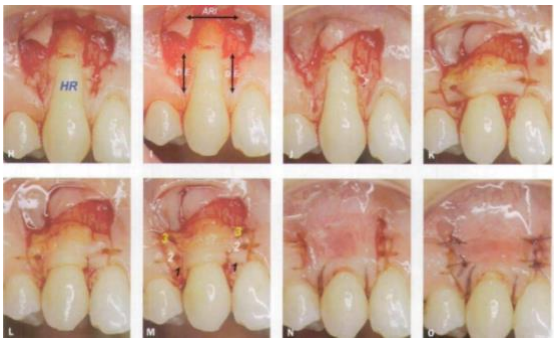

Free gingival graft	CT graft
1- Blood supply from the prepared recipient bed ONLY 2- Contains it's own epithelium **3-** Leaves an open wound in the palate → more discomfort	1- Dual blood supply from the recipient bed + the overlying flap 2- Graft does not have it's own epithelium – it is covered by the flap in the gingiva 3- Wound in the palate is covered again by the flap → less discomfort Higher survival rate ** Used in thin biotype **

Watch the video: Periodontal Surgery – Connective Tissue graft Length 8.30 minutes Dr Soukoulis and Dr Kardachi

Q: when do you need to place a graft ? if the gingiva is thin biotype and there is not enough keratinized gingiva apical to the recession.

If the gingiva is thick biotype or there is enough keratinized gingiva apical to the recession → no need for graft just do coronally repositioned flap

Tunneling technique: you don't create a flap you do a tunnel under the papillae and insert a CT graft – the tunnel should extend beyond the MGJ to allow the tissue to be repositioned coronally

Indications: recessions on multiple teeth [miller's type 1 or RT 1]

Frenectomy: complete removal of the frenum including the muscle attachment – usually used to correct midline diastema - the tissue will heal by keratinized gingiva not alveolar mucosa

Frenotomy : you only do an incision in frenum without removing the muscle attachment and relocate the frenum attachment to create a zone of attached gingiva between the gingival margin and the frenum attachment – frenotomy alone is enough for perio purposes

Causes of excessive gingival display [gummy smile]:

1- Plaque / drug induced gingival enlargements → treated by gingivectomy
2- Anterior dentoalveolar extrusion – mostly caused by untreated early loss of posterior teeth [when the tooth gets extruded it carries with it bone and gingiva]
3- Vertical maxillary excess : long maxillary alveolar process → corrected by orthognathic surgery [but can be treated temporarily but lip botox injections to reduce lip tension]
4- Altered / delayed passive eruption : can be corrected by perio surgery **[crown lengthening]**
5- Short upper lip

Altered Passive Eruption :

Gingival margins fail to recede to the level of the CEJ, after the tooth eruption → gingival tissues are positioned coronal to the CEJ → teeth appear short and square

Lip repositioning when the upper lip is short causing gummy smile but the **clinical crown = the anatomical crown**

Crown-Lengthening:

1- to provide retention form
2- allow proper tooth preparation , impression , and placement of restorative margins
3- adjust gingival levels for esthetics.

Indications	Contraindications
1- Subgingival caries / fracture 2- Inadequate clinical crown height for retention 3- Unequal / unaesthetic gingival heights	1- Surgery will create an un aesthetic outcome [Ex: caries on an incisor in a pt with a high smile line – if you do gingivectomy → the gingival margin will not be at the same level as the adjacent teeth

	2- Caries or fracture will require excessive bone removal on neighboring teeth [bone has to be removed from neighboring teeth to prevent vertical bone defects] 3- Tooth is not restorable

Crown lengthening can be :

A. **Soft tissue resection [gingivectomy only]**: indicated when bone level is at correct height – done to correct uneven gingival margins + expose anatomical crowns
B. **Soft and hard tissue resection -** indicated when bone level is <u>not at the correct height</u>

Q: how can you measure the distance from the bone to the gingiva margin to know if the bone is at the correct height ?

1- Measure sulcus depth
2- Add 2mm [biological width]
   Ex: If your pocket was 4 mm → Distance from bone to gingival margin is 6 mm

- If there is adequate attached gingiva + the distance between bone and gingival margin is **more than 3 mm** → you can do **gingivectomy/ flap surgery [soft tissue removal only]**
- If there isn't enough attached gingiva or the distance between the gingival margin and the bone is **less than 3 mm** → open a flap and remove bone [**bone is only removed buccaly and lingually never interdentally]**

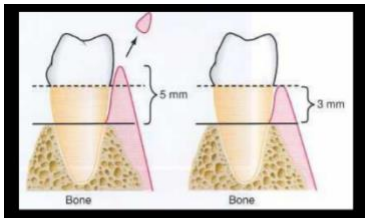

Greater than 3 mm of soft tissue between the bone and gingival margin, with adequate attached gingiva, allows crown lengthening by gingivectomy.

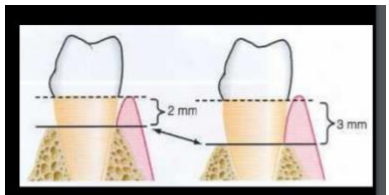

With less than 3 mm of soft tissue between the bone and gingival margin, or less-than-adequate attached gingiva, a flap procedure and osseous recontouring are required for crown lengthening.

- In the case of **caries or tooth fracture**, to <u>ensure margin placement on sound tooth structure</u> and <u>retention</u> form, the **surgery should provide at least 4-5 mm from the apical extent of the caries or fracture to the bone crest [2 mm ferrule + 1 mm sulcus + 2 mm biological width]**

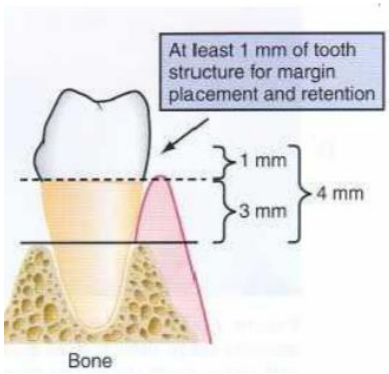

If the bone level is at the level of the CEJ → you must reduce it by 2 mm [If the bone level was at the level of the CEJ and you did not remove it with the soft tissue → gingiva will grow back coronally again.]

Incisions for crown lengthening should be at the level of the CEJ

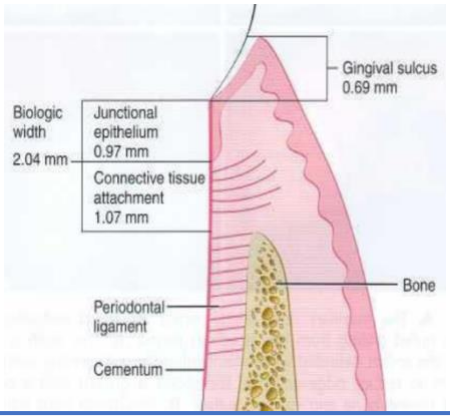

Biological width[BW]

BW = Junctional epithelium [0.97mm]+ the CT attachment [1.07 mm]

Gingival sulcus is NOT a part of the BW [Healthy gingival sulcus depth is **0.69mm]bone loss and reestablishmenet fo**

If the biological width is violated [placing a restoration margin withing the BW attachment] it will lead to one of the following:

- Continous gingival inflmmation + bleeding and swelling [no CAL]
  OR
- Bone loss + re establishment of the BW more apically

Q: what are the consequences of placing crown margin in the biological width ? gingival inflammation + pocket formation + bone loss

NOTE : if there is at least 3.0mm distance between the gingival margin and bone crest. Placement of the restorative margin 0.5 mm into the sulcus allows for the maintenance of the biologic width

Periodontal assessment and management in fixed prosthodontics

Q: Reasons for establishing periodontal health before performing restorative dentistry?

1- To establish stable gingival margins before tooth preparation
2- Provide adequate tooth length for retention, tooth preparation, impression making, and finishing of restorative margins
3- The resolution of inflammation may result in the repositioning of teeth or soft tissue and mucosal changes.
4- Traumatic forces placed on teeth with ongoing periodontitis may increase tooth mobility, discomfort, and the rate of attachment loss.
5- Successful esthetic and implant procedures may be difficult without specialized periodontal procedures .

Q: why should you extract hopeless teeth ? because if they remain without perio treatment they will cause bone loss on the adjacent teeth

Q: when should you re evaluate after perio treatment? After 4 weeks

Preprosthetic surgeries done before fixed prostho:

1- **Mucogingival problems** : increase width of attached gingiva by free gingival graft or apically repositioned flap → to enhance plaque removal around gingival margins + improve esthetics + reduce inflammation around restored teeth.

At least 2 months of healing is recommended after soft tissue grafting procedures, before initiating restorative dentistry

2- **Preservation of ridge morphology after extraction** : placing bone grafts in extractions sockets **Best used if you are doing a bridge with ovate pontic** – you place bone graft in the extraction socket and a temporary bridge with ovate pontic [because it gives the best emergence profile] - initially the pontic is long but you will keep on trimming from it during healing. – this way the pontic will shape the gingival margin giving the appearance of **"emerging through the socket"**

3- **Alveolar ridge reconstruction [after bone loss has already occurred]:**

A. **If the defect is small or you are placing an esthetic pontic** → soft tissue ridge augmentation [you can take a CT graft from the palate and place it in the defect]

B. **If the defect is large or you are placing an implant** → hard tissue ridge augmentation **–** bone graft + membranes [Gortex or titanium reinforced]

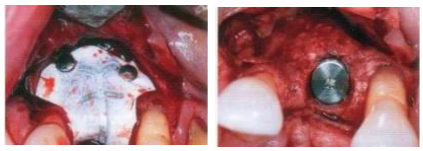

4- **Crown lengthening procedures**

Options for margin placement:

1- **supragingival** [least impact on periodontium – choose this one whenever possible]
2- **Equigingival** (even with the tissue) - **** Has risk of creating recession** traditionally was not desirable because they were thought to retain more plaque than supragingival or subgingival margins and result in greater gingival inflammation + any minor gingival recession would expose the margin. These concerns are not valid anymore: because **restoration margins can be blended with the tooth and finished easily to provide a smooth, polished interface at the gingival margin →** both supragingival and equigingival margins are well tolerated.
3- **Subgingival [** has the greatest biologic risk because these margins are not as accessible as for finishing + if it is placed too far below the gingival margin → it violates the biological width leading to inflammation + pocket formation + bone loss]

Rules for placing subgingival margins in esthetic areas

- **Rule 1:** If the sulcus = **1.5 mm or less** → place the restoration **margin 0.5 mm below the gingival margin**.
- **Rule 2:** If the sulcus = **more than 1.5 mm** → place the margin **half the depth of the sulcus below the gingival margin**. [if the pocket depth = 2mm → **place the margin 1 mm below the gingival margin]**

- **Rule 3:** If a sulcus = **greater than 2 mm** → evaluate to see if a gingivectomy could be performed to lengthen the teeth and create a 1.5-mm sulcus. Then place the margin 0.5 mm below the gingiva. If gingivectomy cannot be done → follow rule 2

Q: pt has a sulcus depth of 2mm and you need to place the margins sub gingivally what happens if you place the margin 0.5 mm away ? and 1.5 mm away ? 0.5 mm away → risk of recession - 1.5 mm away → risk of violating BW

Q: A pt comes to you saying that they placed restorations anteriorly a few months ago and now the margins are showing, what is the cause and what should you do?

Mostly the margins were placed equagingivally which led to recession and margin exposure. Management would be measuring pocket depth and then deciding if we can place the margins sub gingivally or gingivectomy has to be done then place the margins 0.5 mm away from gingival margin

Violation of the biological width on one side only → you cannot remove interproximal bone because you will create a deformity [black triangles and the tooth will look longer than the adjacent] - the pt has to be treated by **otho extrusion**

If crown lengthening alone will result in un esthetic appearance → do ortho extrusion then crown lengthening

Managing interdental papilla :

- Bone crest to gingival margin facially = 3mm
- Bone crest to gingival margin interproximally = 4.5 – 5 mm

The probability of complete fill of gingival embrasure by papilla is determined by the distance from apical to the contact point to the bone crest **[as the distance B/w the alveolar crest and contact point increases the chance of papilla fill decreases]**

- If the distance **is 5 mm** from **crest of bone to the apical contact point → 98% chance of complete fill of the space**.
- If the distance is **6 mm** from **crest to contact** → 56% chance
- If the distance is **7 mm** from **crest to contact** → 27% chance

Tapered teeth :have large & BLUNT interdental papilla + shallow sulcus [the contact point is more coronally → less chance for papilla fill]

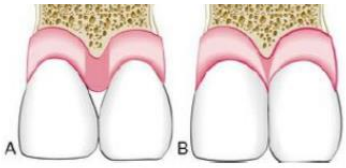

Squared teeth : the contact point is more apically → higher chance for papilla fill but the sulcus is deeper

Open gingival embrasures are caused by excessively tapered tooth form , to increase the chance of papilla fill → decrease the distance between the contact point and the bone **by moving the contact point more apically** [but this will make the teeth more square and bulky + less esthetic]

Q: what is the best way to close the open gingival embrasures? Place the margins of the restoration 1-1.5 mm below the tip of the dental papilla [this way the teeth can easily be cleaned because of the convex shape]

To ensure optimum gingival health :

1- Restoration should have correct contour and well fitting margins
2- Temporary crowns should be well fitting

Q: how can you do gingival recontouring?

- Mechanical (Surgical) – gingivoplasty, apically or coronally repositioned flap
- rotary diamonds
- Electrosurgery

If electrosurgery is used for gingival recontouring , **place retraction cord in the sulcus** to protect the attachment from the electrosurgery tip + the tip should be **parallel to the restoration and resting on the placed retraction cords [**This removes a minimal amount of tissue] – if you tilt the tip → excessive tissue removal and you might touch the bone and end with bone necrosis

NOTES:

- Dry retraction cords can peal the epithelium from the sulcus and cause abrasion
- Overly large retraction cord can cause recession
- Impression material remaining in the gingival crevice → can cause periodontal abscess
- Insufficient embrasure space → traps interdental papilla and causes continuous inflammation

References

- Newman, M. G., Takei, H. H., Klokkevold, P. R., & Carranza, F. A. (2012). Carranza's clinical periodontology. St. Louis, MO: Saunders Elsevier.
- Lindhe, J., Lang, N. P., & Karring, T. (2008). Clinical periodontology and implant dentistry. Oxford: Blackwell Munksgaard.
- J. D. Manson, B. M. Eley - Outline of Periodontics
- Brazier et al. Ecstasy related periodontitis and mucosal ulceration - a case report.British Dental Journal 2003;194:197-199.

Disclaimer

By using Dentiscope, you understand that:

> This is a non-profit project established by the founders, purely with the intention of relaying knowledge to dental students and young dentists around the world.
> None of the contents should be sold, replicated or translated without prior formal and written consent from the team.
> This is NOT a substitute for medical resources and formal education.

Limitation of liability:

> There may be mistakes in the published content, although it will be reviewed thoroughly before publication. It should be noted that peer-to-peer learning methods are very helpful as learning tools but their limitations should be kept in mind as it relies on the students own experience and understanding of the topic.

> Information posted is all believed to be accurate and useful at the time of posting. All efforts have been made to review content thoroughly. Before performing any procedure, or applying any of the knowledge we have supplied, we recommend and stress that you refer to certified specialists and recent medical literature for accurate evidence. Neither Dentiscope, the content writers, content reviewers or editors can accept any legal liability or responsibility for any errors made. Your reliance on any content from Dentiscope is at your own risk.

Ownership:

All trademarks and logos are under the rightful ownership of the team of Dentiscope

Content:

All copyrights are respected, for any comments or complaints on any of the references used, please contact the team on the email provided.

By submitting your content on Dentiscope you agree that:

> You will be recognized as the content writer by name as long as your contribution remains on Dentiscope
> Your content will be displayed on the Dentiscope website and other forms of social media including (but not limited to): Instagram, twitter and youtube.
> You've allowed Dentiscope a loyalty free license to edit, publish, and publicly display your contribution. You've also allowed Dentiscope to reformat and use your material as best as we see appropriate.

DENTISCOPE.ORG

ASK@DENTISCOPE.ORG

DENTISCOPE