Cervical vertebra

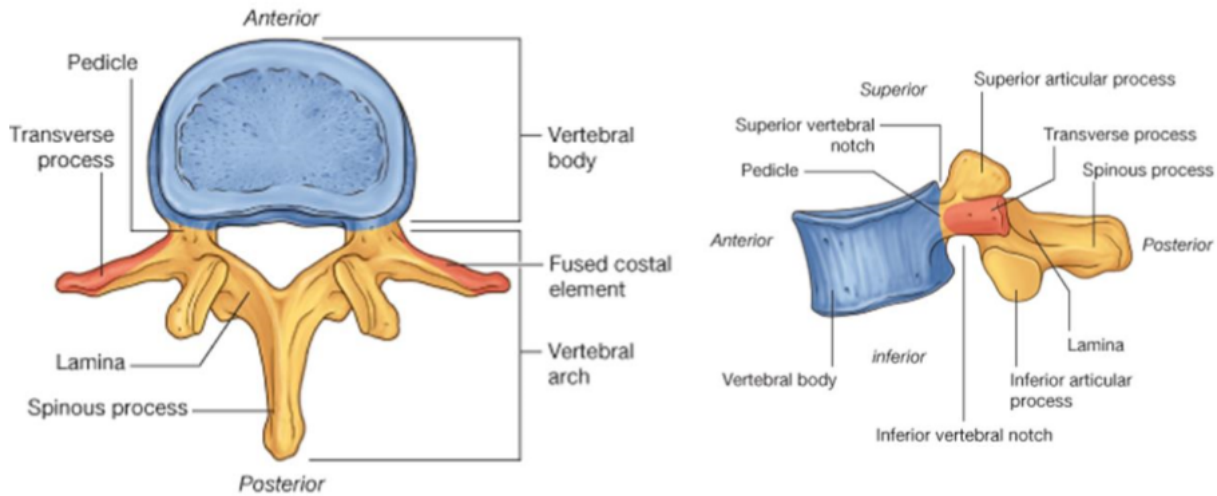

Typical vertebra

Typical vertebrae `	
Body	Vertebral arch
	• 2 pedicles • 2 laminae • 7 processes [2 Superior articular Processes - 2 inferior articular Processes - 2 Transverse Processes - Spinous Process] • Spinal Foramen • Intervertebral Foramen

Spine curvatures :

- **2 secondary curvatures →** cervical and lumbar curvature
- **2 primary curvatures →** thoracic and sacral curvatures

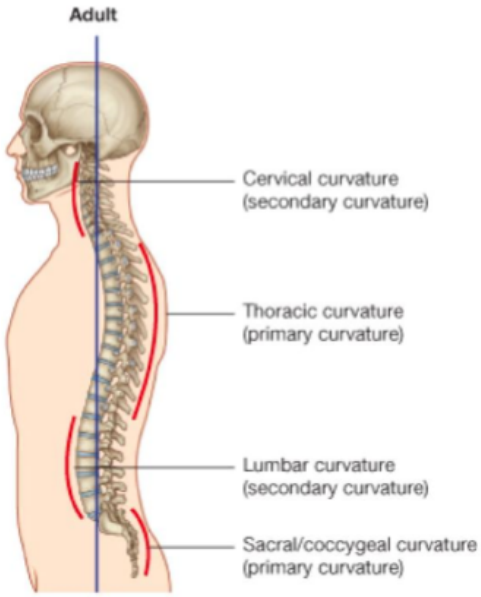

Vertebra :

- Cervical = 7 small vertebra , have formen in their transverse process
- Thoracic = 12 larger vertebra , have an (facet) articulation at the side of the body
- Lumbar = 5 larger – carry all of the vertebra superior to them
- Sacral = 5 fused vertebra that form the sacrum

Vertebral foramen : foramen located at the center between the vertebral arch and body . where the spinal cord is running , when the vertebral foramina are arranged over each other they will form the vertebral canal

Intervertebral foramen :

Space located in between 2 vertebrae to allow the exit of the spinal nerves.

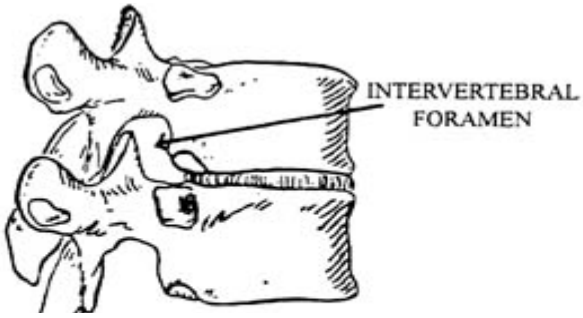

[spinal nerves – that exit the spinal cord] :

- 8 cervical nerves
- 12 thoracic nerves
- 5 lumbar nerves
- 5 sacral nerves

CERVICAL VERTEBRA :

Characteristic feature : has a transverse process with a foramen in it called for amen tansverserum or transverse foramen.

Encloses the vertebral arteries and the sympathetic plexus.

The spine is short and bifid. And has a notch at the posterior end .

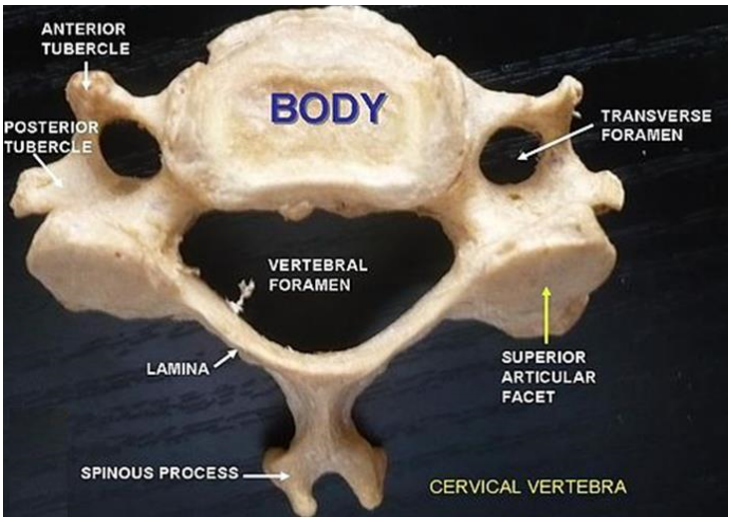

THORACIC VERTEBRA :

Characteristic feature : has costal facets [articulation surface on the side of the vertebra for the articulation with the ribs]

The spine is long and **not bifid**.

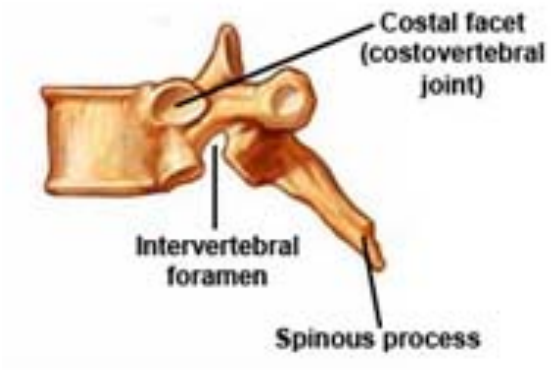

LUMBAR VERTEBRA :

Characteristic feature: larger than thoracic vertebra [because they carry all of the vertebra superior to them] , typical vertebra [no facets on the side , and no transverse foramen]

SACRAL VERTEBRA :

The 5 sacral vertebra are fused together to form the sacrum the intervertebral foramina are indicated as the anterior sacral and posterior sacral foramina [since the spinal nerves in this region divide into ventral roots that exit through the anterior sacral foramina and the dorsal roots that exit through the posterior foramina]

CERVICAL VERTEBRA [7 vertebra]

Articulations :

1. Between the 2 bodies of the 2 adjacent vertebra → vertebral disc (secondary cartilaginous joint – to allow limited mobility between the 2 vertebra).
2. The superior articular process articulates with the inferior articular process of the vertebra above. (the joint in between them is synovial plane joint – allows lmited gliding movement)

FIRST CERVICALL VERTEBRA [ATLAS]

Characteristic features : absence of body + prescence of 2 lateral masses [the superior surface of each lateral mass shows a **kidney shaped facet** that articulates with the occipital condyles of the occipital bone forming the **atlanto occipital joint** **[synovial ellipsoid of synovial condyloid joint]** that allows the **nodding movement of the head – flexion and extension of the head** ***like when you say YES***].

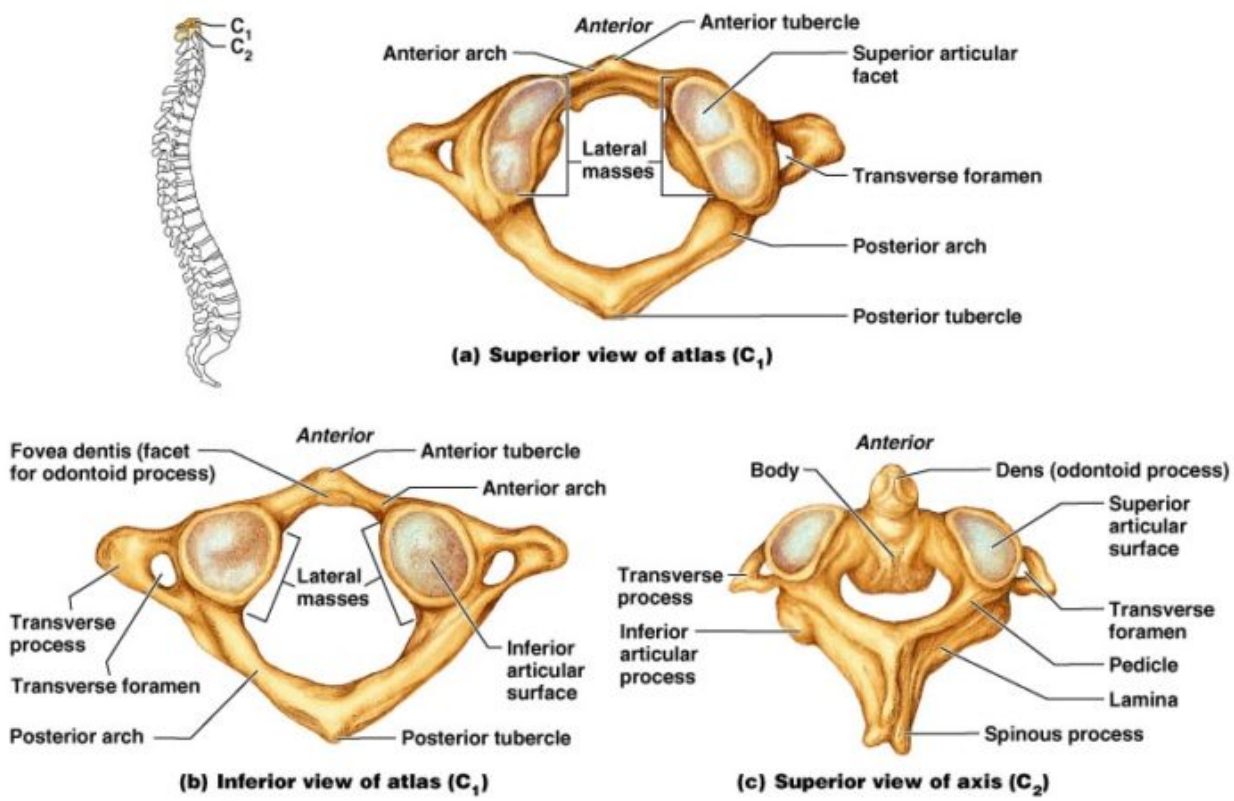

Atlas has 2 arches :

- Anterior for articulation with the AXIS (second cervical vertebra)
- Posterior (larger) with a groove that accommodates the dorsal ramus of C1 and the vertebral artery

The inferior surface of ATLAS has an oval articulating facet to articulate with the AXIS by the **atlantoaxial joint** [**synovial plane joint – allows gliding movement rotating movement** ***like when you say NO***]

Articulations of ATLAS	Name of joint	Type of joint	Type of movement
Between the superior kidney shaped facet of the ATLAS and the occipital condyles of the occipital bone	Atlanto – occipital joint	Synovial ellipsoid or synovial condyloid	Flexion and extension of the head [nodding movement like when you say yes]
Between the inferior oval shaped facet of the ATLAS and the AXIS	Atlanto – Axial joint	Synovial plane	Gliding / rotating movement [like when you say no]

SECOND CERVICAL VERTEBRA [AXIS]

Characteristic features : large body with odontoid process and a thick bifid spine

Articulations of the AXIS & ATLAS		Name of joint	Type of joint	Type of movement
Lateral side	The inferior articular process of the ATLAS with the inferior articular process of the AXIS	Lateral AtalntoAxial joint	Synovial plane joint	Both the laterla and the median AtlantoAxial joints work together to move the head in a rotatory movement
Middle	Between the otondoid process and the anterior arch of ATLAS The otontoid process rotates along a ligament called transverse cervical ligament	Median AtlantoAxial joint	Synovial pivot joint	

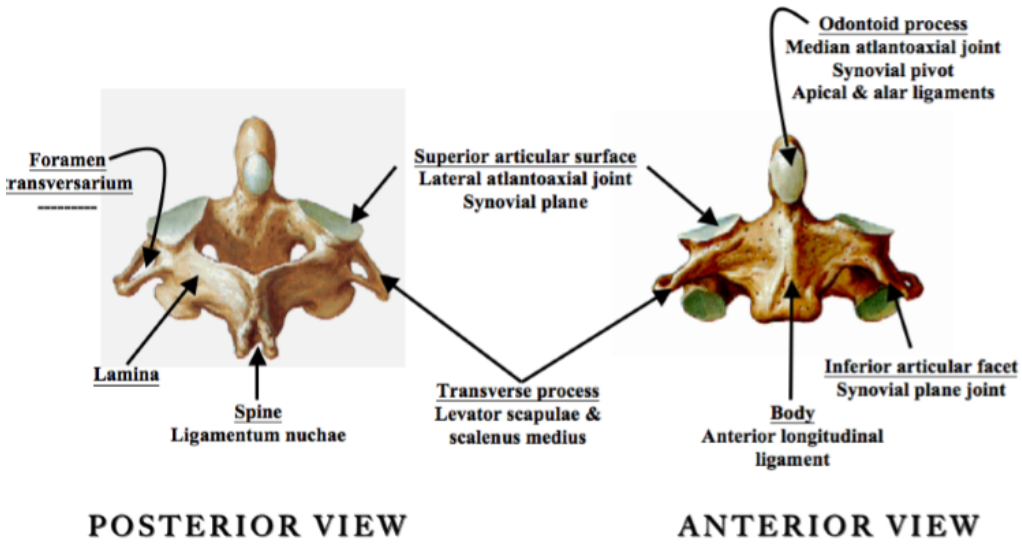

Anteriro surface of odontoid process shows the articulation with the anterior arch of ATLAS.

Posteriorly it shows a groove for transverse liagment that forms the ring for the median atlanatoaxial joint

3,4,5,6 CERVIAL VERTEBRA : typical vertebra [all are the same shape and have the same features]

7TH LAST CERVICAL VERTERBRA :has body and verebral arch but the **spine is long and not bifid. [they will resemble the lumbar and thoracic vertebra]**

NOTE : all cervical vertebra have 2 transverse processes with a foramen in each . anterior tubercle for the attachment of scalenus anterior muscle and the posterior tubercle for the attachment of the scalenus medius and scalenus posterior muscles .

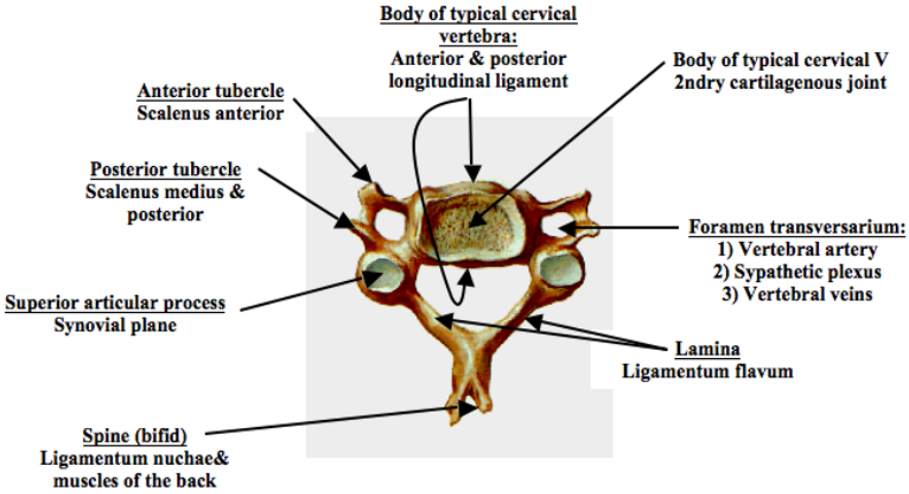

TYPICAL CERVICAL VERTEBRA

LIGAMENTS :

Continuous along all vertebra but some change their name in the cervical region .

1. Transverse cervical ligament → ring shape for the rotation of the otondoid process of the second cervical vertebra

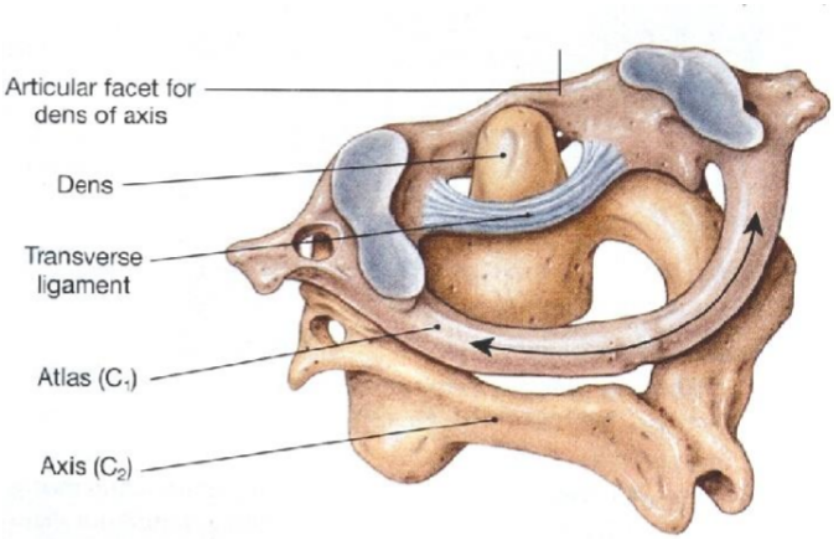

	ANTERIOR LONGITUDINAL LIGAMENT	POSTERIOR LONGITUDINAL LIGAMENT
LOCATION + EXTENSION	Dense band along anterior and lateral surface of the vertebral bodies from [C2 to sacrum] [From C1 to skull, called Atlanto-Occipital Membrane – stabilizes the atlanto occipital joint] Attached to the intervertebral discs posteriorly to reinforce them	Runs along posterior surface of vertebral bodies (anterior to spinal canal) [C2 to Sacrum]
FUNCTION	**Limits extension** of Vertebral column	Reinforce the inter vertebral discs posteriorly Superiorly, continues to occiput, called Tectorial Membrane **Limits flexion**

The transverse ligament and the posterior longitudinal ligament form the cross-shaped ligament between [ATLAS + AXIS + occipital bone] to stabilize the joints and make those 3 bones as one unit

Supraspinous ligament :

- Spinous process to spinous process – tip to tip
- C7 to sacrum
- **Limits flexion**
- In cervical region, **<u>becomes much thicker with a greater elastic content and called Ligamentum Nuchae</u>**

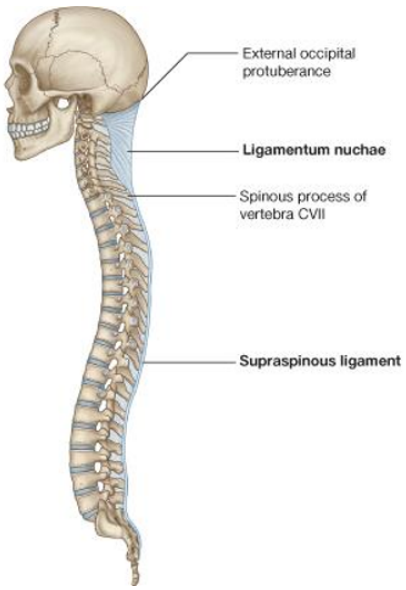

Ligamentum Flavum :

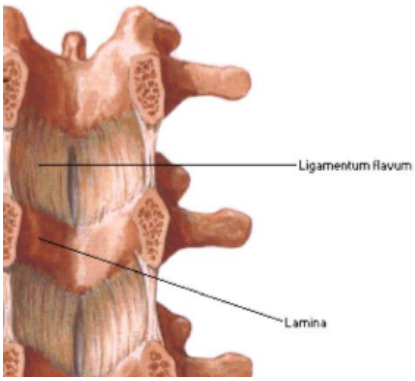

- Connects lamina of one to lamina of the other
- Found from axis to sacrum
- **Limit flexion**
- Continuation to the skull is called **Posterior Atlanto-Occipital membrane.**

Intervertebral Disc :

- Fibrocartilaginous joints
- Increase in size from Cervical to Lumber (3mm to 9 mm)
- Ratio remains the same
- Make up 20-30% of length of column

Osteoarthritis → pain due to the friction between the 2 vertebra if the intervertebral disc tears.

Disc prolapse→ hernia of the intervertebral disc , the disc will bulge press on the nerve causing pain in the area that this nerve supplies (if this nerve supplies the lower limb patient feels pain in the leg)

LIGAMENTS	LOCATION
Anterior longitudinal ligament [ALL]	Anterior surface of all bodies of all vertebra
Posterior longitudinal ligament [PLL]	Posterior surface of all bodies of all vertebra
Supraspinous ligament [SP]	Running along the tip of the spines of all vertebra – after C7 it is called ligamnetum nuchae
Ligamentum flavum [LF]	In between the laminae of all vertebra posteriorly

- All ligaments located posteriorly [PLL , SI , LM] → limit flexion
- All ligamnets located anteriorly [ALL] → limit extension