Dentin structure and function

Dentin pulp complex :

Dentin and pulp are related :

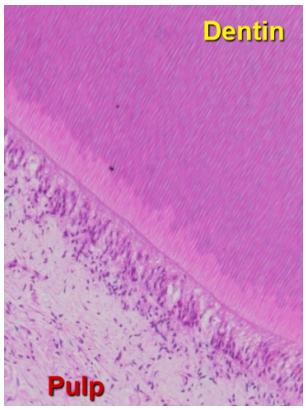

- **Embryo logically** (Recall : dentin and pulp origin → dental papilla)
- **Functionally** (dentin protects the pulp from insults and injury and since it has the odontoblasts it responds to injury)
- **Histologically** (since the odontoblast bodies are located at the border of the pulp and the processes extend along the dentin until they reach the DEJ)

— The pulp & dentin form an integrated tissue, with the **dentin being the calcified product of the pulp and the pulp providing vitality to the dentin.**

— Dentin forms the bulk of the tooth and provides general form and shape to the tooth , covered by the enamel of the anatomic crown and by the cementum of the anatomic root .

— Dentin and enamel are bound firmly at the DEJ

— In the root , the junction b/w dentin and cementum is less distinct **.**

The functions of the dentin:

1. Forms the shape of the tooth
2. Protects the pulp
3. Supports the enamel
4. Dentin genesis – differentiation of odontoblasts and secretion of dentin induces the differentiation of ameloblasts to form enamel .
5. Responds to injury
6. Sensitive (due to the presence of the tissue fluid)

General characteristics of dentin :

1. Unique tissue of teeth
2. Avascular but cellular , since it contains the odontoblast processes
3. Not replaced if damage but has the capacity to repair by deposition of tertiary dentin .
4. Vital tissue contains the cellular part of odontoblast cells , can also respond to injury
5. Sensitive – pain associated with caries and exposed surfaces
6. Dynamic : the composition of dentin is not stable throughout life
   Ion exchange with the surrounding environment (DEM ←→REM)

Enamel	Dentin	Cementum	Pulp
Avascular	Avascular	Avascular	Vascular
A cellular	Cellular	Cellular	Cellular

NOTE : Dentin receives nutrition from the pulp through the tissue fluid .

Physical properties of dentin :

1. D has elastic quality (will not change shape under forces – no deformity) this is very imp. For the proper functioning of the tooth and prevents fracture of the brittle enamel under masticatory forces .
2. The color of dentin varies from light yellow in deciduous teeth to pale yellow in permanent teeth , becomes darker with age (since the dentine increases in thickness with time and the enamel goes through attrition with age)

   Light readily passes through enamel and can be reflected by the undelying dentin . the thick enamel does not permit light to pass through , so in this case the crown appears whiter .
3. Dentin is slightly harder than bone & cementum .
4. Cracking of D is more likely in older teeth (sclerotic dentin = dentin become more mineralized) & in teeth with root canal therapy (D is dehydrated , no tissue fluid)
5. D is less resistant to attrition / abrasion / erosion than enamel – on radiograph dentine is less radiopaque than E .
6. The tubules architecture & organic matrix provides :
   - Great compressive strength (D= 297 E= 384 Mpa)
   - Higher tensile strength than enamel (D=98 E = 10 Mpa)
   - Higher flexural strength than enamel

— More resistance to fracture than enamel .

7. D is highly permeable depending on the size and patency of dentinal tubules , permeability decreases with age .

   Permeable to small molecules :

— Potential for therapeutic substances applied to an exposed dentin surface to diffuse to the pulp (Calcium hydroxide (dycal) encourages the formation of dentin)

— Potential for topical agents to re mineralize dentin

— Outward movement of the dentinal fluid affects the use of adhesive material (that's why the operative fluid should be very dry)

8. Low thermal conductivity – protects the pulp from insults due to heat
9. low thermal expansion

Q:Why is the Incisal 3rd is more whiter than cervical 3rd ? because enamel is thicker in the incisal 3rd (less dentin) and in the cervical region the enamel is thinner and the color is due to the underlying dentin .

Q:what is non vital dentin? Dentine with **No tissue fluid** , teeth with root canals that's why they usually put crowns to protect the tooth from fracture (since dentine is not vital)

Q:Explain what is mostly likely if a patient comes with one tooth darker than the rest ? this tooth lost vitality mostly due to trauma , non vital teeth fracture easily so you mostly treat them with RCT and overlaying crown .

Recall : if it was staining due to coffee or smoking it would be generalized not on a single tooth

Q:Why does the dentin inc. in thickness with age ? because dentine is only deposited and there is no resorption of dentin (unlike bone which undergoes deposition and resorption)

Q:When does the dentin undergo resorption ? During exfoliation of teeth (shedding of teeth)

- Attrition in dentin is much faster in dentin compare to the enamel (since denine is 70 % inorganic compared to the enamel

Q:Arrange the following structures according to their radio opacity from highest to lowest ?

1- Enamel (highest)
2- Dentin
3- Alveolar bone
4- Cementum (lowest)
Pulp and PDL = radiolucent

Chemical composition of dentin :

Mature dentin is made up of :

70 % inorganic	20% organic	10% water
Similar in shape but much smaller HA crystals than the enamel. **$Ca_{10}(Po4)_6(OH)_2$** 1. Carbonate- high (more susceptible to caries) 2. Fluoride 3. Sodium **4.** Magnesium	90% of organic content is collagen fibrils : Type 1 (dominates) Type 3 Type 5 10% of organic content: 1. is non- collagenous proteins 2. lipids 3. peptides 4. osteonectin 5. glycoproteins 6. proteoglycans	

Functions of the organic components of dentin:

1. Collagen	**Rigidity – type 1 acts as a scaffold that accommodates minerals in the fibrils**
2. Phosphoproteins – DPP	**Bind to large amounts of calcium (since it has high –ve charge) , binds to collagen , and it is able to initiate crystal formation**
3. Sialoproteins – DSP	**In peritubular dentin : Inhibits it's growth and thus prevents the DT occlusion.**
4. Sialophosphoproteins – DSPP	**DSPP mutations results in dentinogenesis imperfecta**
5. Growth factors	**Induce the production of tertiary dentin**
6. Enzymes	**Catalyse reactions**
7. Phospholipids	**Role in mineralization , found in predentin and dentin**
8. Proteoglycans	**More in predentin , prevents premature mineralization until the collagen fibrils attain their final dimension**

Recall : dentin is first secreted as a matrix which is collagen + ground substance later it will undergo mineralization (crystal formation by the help of the Phosphoproteins)

Occlusion of D :

- The body and the processes of the odontoblasts will secrete dentin .
- Dentinogenesis imperfecta also affects bone .

Types of dentin :

In relation to DT :

- Peritubular (intratubular)
- Intertubular (forms the bulk of the dentin

According to time of formation :

- Primary dentin
- Secondary dentin

In response to injury :

- Tertiary (reparative or reactionary)
- Sclerotic dentin- could be related to aging or in response to chronic injury
- Dead tract

Defect In the mineralization :

- Interlobular or globular dentin

Intratubular dentin (peritubular)	Intertubular dentin
1. Within dentinal tubules 2. Hypermineralized ring of dentin (more mineralized than intertubular dentine & contains less collagen fibrils) 3. Formed soon after intertubular dentin 4. Odontoblast processes involved in the transport of this dentin from cell body to form it . (the secretory vesicles are formed by the body of the odontoblasts and carried by the process and secreted around the process) 5. More near DEJ (since the odontoblasts begin secretion at the DEJ) **6.** Occupies 2/3 of dentin	1- Located between dentinal tubules 2- Forms the main body of the dentin 3- Represents the primary secretory product of odontoblast, consists of network of type 1 collagen fibrils in which appetite crystals are deposited .

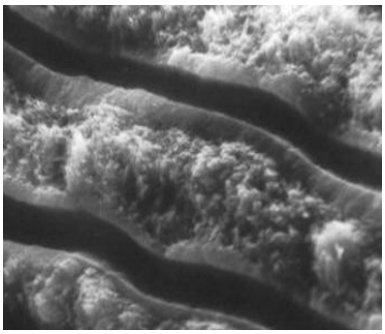

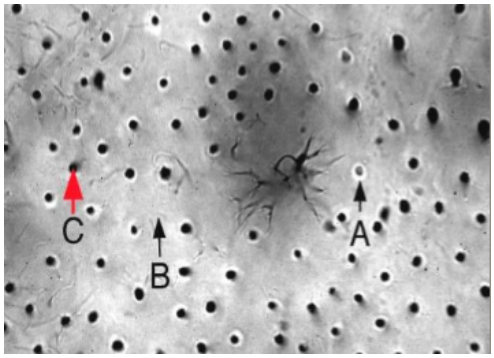

Dentinal tubules have :

1- Tissue fluid
2- Ending of nerve fibrils
3- Odontoblast process
The wall is formed by the **peritubular dentin**

Primary dentin	Secondary dentin
Dentin formed during the development of the tooth , it's formation ends when the root formation is complete . **(from late bell stage until the closure of apical foramen – after eruption)**	**Formation starts after complete root formation .**
Mantle dentin : a narrow zone at the outermost layer of primary dentin . **-First dentin that is formed and calcified it is visible as a band (10 um) close to the Dej or the CDJ** **-Has more peritubular dentin that the dentin surrounding the pulp region** In the crown : **collagen fibrils are perpendicular to the DEJ** In the root **: collagen fibrils are parallel to CDJ.**	-It is formed on the floor and roof of the pulp chamber which causes the pulp chamber to decrease in in size by time (pulp recession) And dec in the height of the pulp horns -It is deposited at a slower uniform rate than primary dentin -The ratio of organic and inorganic Issimilira to primary dentin .
Circumpulpal dentin : the main bulk of dentin . **-It outline the pulp** **-**Formed and calcified after mantle dentin **collagen fibrils parallel to DEJ.**	-the junction between primary & secondary dentin is characterized by a demarcation line (a slight difference in the staining) since the DT are less regular in their organization
Formed 4 um per day	**Formed 1 um per day**

T/ F : The only part of primary dentin that has diff orientation of collagen fibrils in only in the crown ? TRUE

- What causes pulp recession ? secondary dentin
- What is the first dentin formed ? primary dentin

Tertiary dentin :

It is deposited at specific sites in response to injury (caries , attrition , abrasion , cavity preparation)

The rate of deposition depends on the degree of injury , the more severe the injury the more rapid rate of dentin deposition .

As a result of this rapid deposition , cells often become trapped in the newly formed matrix , and the tubular pattern becomes grossly disorted .

Tertiary dentin is sub classified to :

- **Reactive dentin :** deposited by preexisting odontoblasts
- **Reparative dentin :** deposited by newly differentiated odontoblast like cells

Types of tertiary dentin : the one sharing feature is that they all form underneath the stimuli .

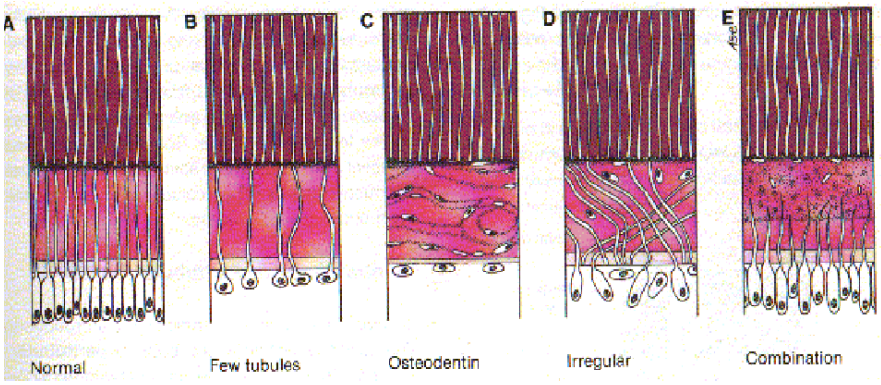

Different histological features of the tertiary dentin ?

It depends on the severity of the stimuli

1) If the stimulus is still in the enamel (mild stimuli) → tertiary dentin that is **regular with few tubules** – like secondary dentin but less # of tubules due to the mild stimuli (the odontoblasts had enough time to produce the dentinal tubules)
2) If the stimulus is closer to the pulp (severe stimuli) →
    - **osteodentin** , tertiary dentin resembling bone having cell inclusions of fibroblasts , odontoblasts , blood cells .
    - denitn Irregular with few tubules , when the dentin is laid down rapidly it appears irregular with twisted tubules
    - combination : irregular + twisted tubules + cell inclusions all in one

Type	Location	Description
Peritubular	Wall of DT	Highly calcified
Intertubular	Between the DT	Less calcified than peritubular
Mantle	Adjacent to DEJ & DCJ	First dentin formed
Circumpulpal	Form along the entire pulp-dentin border	Formed after mantle
Primary	Continue to form until the complete formation of apical foramen	Formed rapidly
Secondary	Start to form after completion of apical foramen	Formed slowly
Tertiary	Forms as a result of injury	Regular or irregular pattern of tubules

Sclerotic dentin :

Occlusion of DT by :

1- peritubular dentin as a physiological response
2- deposition of minerals within tubule without dentin formation
3- diffuse mineralization is occurring in the presence of viable odontoblast process
4- mineralization of the process and collagen fibrils of DT

appearance : dentin assumed a glassy appearance and becomes translucent

causes :

- increase with age and it is most **common in the apical 3rd of the root** .
- sometimes due to noxious stimuli as in chronic caries irritated odontoblasts forms sclerotic dentin as a protective wall

Q:explain why extraction in some cases of elderly patients is very hard an results in the fracture of the apical 3rd of the root ?

Due to formation of sclerotic dentin and the deposition of peritubular dentin in the DT in the apical 3rd of the root (becomes hard like enamel)

Interglobular Dentin :

Areas of unmineralised or hypomineralised D where globular zones of mineralization failed to fuse into a homogeneous mass within the dentin .

Common in people with vitamin D deficiency or high levels of Fl- at the time of dentinogenesis

Location : often between mantle and circumpulpal Dentin (because the type of mineralization in this region is globular type)

Structure : no peritubular dentin but normal pattern of DT (because the defect is only in the Dentin mineralization)

Dead tracts :

Dark areas that are sometimes found in dentin .

Cause : due to the complete retraction of osteoblast processes either as a reaction to attrition or severe injury or stimulus as in operative procedures → DT is filled with air

Appear dark in ground sections and **this area is sealed with reparative dentin**

What ae the contents of DT with these types of dentin ?

	Peritubular	**Odontoblast process**	**Tissue fluid**	**Terminal nerve ending**
Primary dentin – mantle	Yes	Yes	Yes	NO
Primary dentin – circumpulpal	Yes	Yes	Yes	Yes
Secondary dentin	NO	Yes	Yes	Yes
Tertiary dentin	NO	Yes	Yes	Yes
Dead tract	NO	No	No	No
Sclerotic dentin	Yes	Yes	No	No
Interglobular dentin	No	Yes	Yes	No

Circumpulpal dentin is the main bulk of the dentin .

Predentin : you can't see this in ground section

- It is about 2- 3 um wide
- Unmineralized zone between the mineralized dentin and odontoblasts
- It consists of proteoglycans , glycoproteins collagen and fibrils
- It is easily seen by H & E stain , appears lighter than calcified dentin
- Deposited at a rate of 4 um a day & mineralized 2 um every 12 hours **(the thickness remains constant since there is a blanket b/w the formation and mineralization)**
- **Thickest during active dentinogenesis and less in thickness with age**

Q: why can we always recognize predentin around odontoblasts ? because of the balance between mineralization and formation

DentinoEnamel Junction :

- It can be easily seen as a series of scallops with extensions of odontoblast processes , occasionally crossing the DEJ and passing into the enamel to form enamel spindles
- This junction increases the adherence between dentine and enamel

If The DEJ is straight → dentinogenesis imperfect , the enamel is normal but it gets away from dentin because there is no attachment b/w those 2 tissues

DentinoCemental junction :

The junction between cementum and dentin is less distinct due to the intermingle b/w the fibrils of D & cementum

CDJ = relatively smooth in perm. Teeth but sometimes scalloped in deciduous teeth

Enamel spindles :

Projections that are formed when occasionally the odontblast processes may withdraw quickly enough back across the DEJ after touching the preameleoblasts so they remain stuck in the enamel .

- In elderly they might not feel pain during operative procedures since the dentin Is mostly peritubular dentin → non vital dentin so it won't be sensitive to stimuli
- But in younger patients they will feel pain since the dentin is still vital and contains the odontoblast processes and enamel spindles so it is still sensitive

If you want to see all components of dentin → decalcified sectioning

Dentinal tubules :

1. Number varies from 30,000 – 70 ,000 / mm2 (the # varies according to the tooth)
2. Diameter varies : 3 um near the pulp and 1 um near the enamel
3. Extend from pulp to DEJ & CDJ
4. Roughly circular in cross section
5. Taper from pulp to be narrowest at the DEJ
6. Curved
7. Branched , forming a network for nutrients diffusion throughout dentin
8. Lateral branching and terminal branching
   The lateral branches are called canaliculi , 1 um in diameter , at right angle to the main tubules
9. **Contain mainly cytoplasmic processes of odontoblast cells**

Terminal branches of DT :

- Dentinal tubules branch at the terminal ends in the mantle dentin **specially in the root**
- Terminal branches related to the early dentinogenesis during which odontoblast cells containing many processes .
- The DT are responsible for permeability of the dentin and provide pathways for microbial invasion of dentin

Contents of dentinal tubules :

- Odontoblast processes : a single process extends into the DT it contains a few secretory vacuoles and cytoskeleton network.
- Collagen fibrils
- Dentinal fluid
- Nerve fibrils at the inner 3rd of the DT
- DT have very thin inner organic lining or membrane high in GAG called lamina limitans (some believe it is absent)
- Peritubular dentin

Age	*Type of dentin*
Newly erupted teeth	Primary dentin
Perm mand. first molar at the age of 7	Primary dentin (since it erupts at 6 year and the apical foramen needs 3 years to close) Possibility to have tertiary dentin as well (the child might have caries)

Curvatures of dentinal tubules :

1- Primary curvatures : DT follow S shape path , these curvatures called the primary curvatures , **represent the movement of odontblast cells towards the pulp during dentinogenesis**
The s shape curvature is less in root and beneath the incisal edges and cusps almost DT show a straight course .

2- Secondary curvatures : minor curvatures along the length of dentinal tubules
Represents the daily movement of odontoblasts during dentinogenesis of primary and secondar dentin

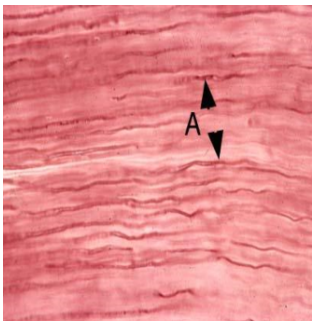

Granular layer of tome's :

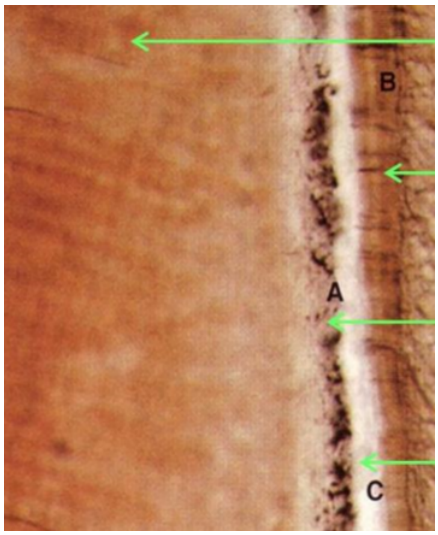

- **Location :** near the DCJ
- **Causes :** looping of the terminal portions of DT , due to special arrangement of collagen and non- collagenous proteins between dentin & cementum
- **Appearance :** black granules- like , more clear in ground sections
  Increasing in the granules occurs from the CEJ to the apex of the root

Incremental growth lines :

1- Von Ebner lines :

Appearance : 90 degrees to DT apart from each other 20 um
Cause : dentin formation occurs incrementally (4 um / day)
Changes of collagen fibrils orientation was seen more clear after 5 day cycle of this daily deposition
So the marked changes in the collagen fibrils → incremental lines

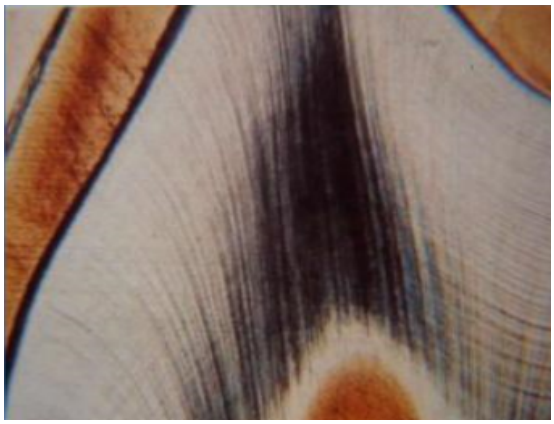

2- **Contour lines of Owen :**

Appearance : so clear in longitudinal ground sections , appeared as dark bands .

Causes : deficiencies in mineralization during periods of illness , changes of body metabolism , or inadequate nutrition .

In some teeth , wide contour line is considered as neonatal line .

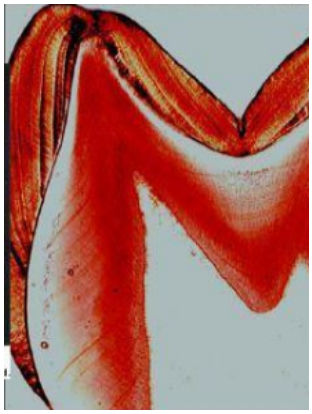

Neonatal line :

It is a line , between prenatal and post natal dentin due to physiological trauma of birth .

Found only in deciduous teeth & 1st permanent molar teeth .

Dentin formed prior to birth is better than after birth .

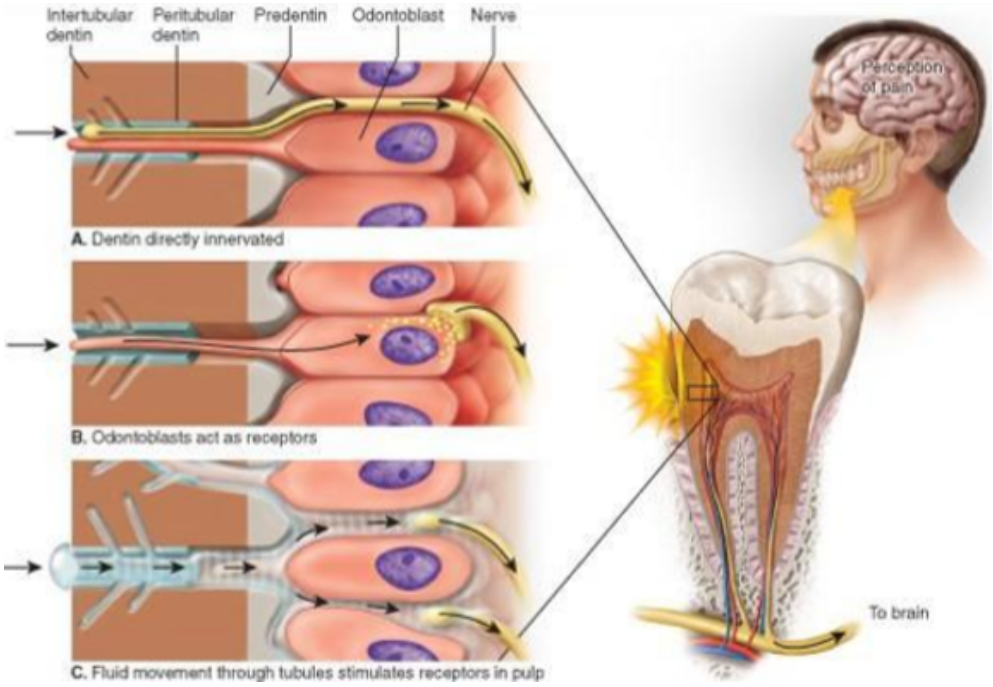

Theories of pain transmission :

A. **Direct neural innervation :** in which the stimuli directly effect the nerve endings in the tubule , but the manners in which stimuli reach nerve endings are yet unknown . (it didn't explain the pain away from the pulp – since we don't have nerve fibers)

B. **Transduction theory :** considers that odontoblasts are a receptor cell because of it's neural crest origin . odontoblastic processes are excited and the impulses are transmitted towards the nerve endings .
   This is not popular because no neurotransmitter vesicles can be found b/w odontoblasts
C. **Hydrodynamic theory :** the most popular theory – stimuli (heat , cold , mechanical , chemical) causes fluid movement within the tubules and stimulates the pain mechanism by mechanical disturbance of nerve endings that closely associate with odontoblasts processes .

Hydrodynamic theory explain all types of pain and the different severities .

Near the pulp DT are wider → more fluid (more severe pain)

DENTISCOPE.ORG

ASK@DENTISCOPE.ORG

DENTISCOPE