General Anatomy (Abdomen)

Abdomen:

Has two walls: anterior abdominal wall and posterior abdominal wall

Anterior wall: rectus abdominis muscle, external oblique abdominis muscle, internal oblique abdominis muscle, transversus abdominis muscle.

Fibers provide strength to the abdominal wall

Rectus abdominis muscle covered with rectus sheath a combination of three muscles (external, internal and transverses)

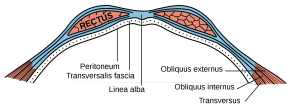

Function of anterior abdominal wall : protects the organs, increase the intraabdominal pressure, can accessory muscle for respiration, help in the flexion of the spine.

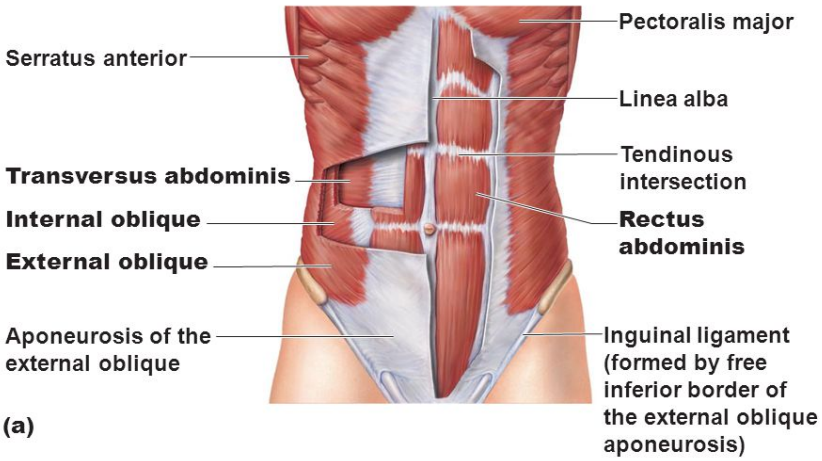

Posterior wall:

- Quadratus lumborum muscle (function: lateral flexion of the spine).
- transverses abdominus muscle (forms a belt around the abdomen).
- psoas major muscle (flexes spine and hip).
- psoas minor muscle (flexes the spine).

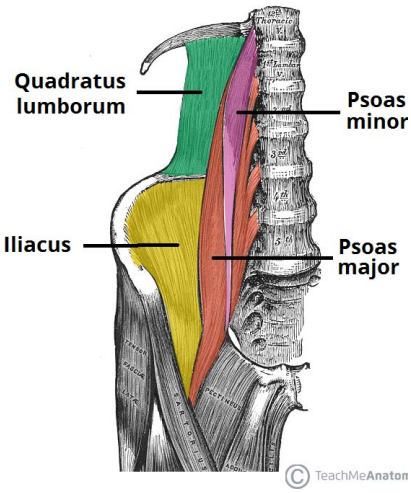

Iliac crest : The iliacus muscle is a fan-shaped muscle that is situated inferiorly on the posterior abdominal wall. It combines with the psoas major to form the iliopsoas – the major flexor of the thigh.

Protects the posterior organs of the abdomen

BY : Haif AlQahtani & Jenan almahfoudh

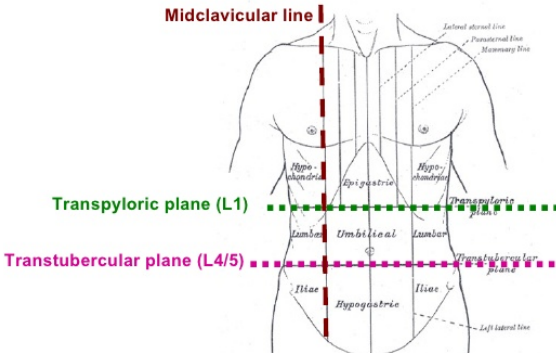

Abdominal regions:

At the top: xyphoid process lateral to it costal margin

Midclavicular line > right and left > vertically
Transpyloric line >pass through the pylorus > horizontal
Transiliac line > passes through iliac crest > horizontal

9 regions:

From the left side:

- **Right hypochondrium:** contains the liber and the gallbladder
- **Epigastrium:** contains the stomach
- **Left hypochondrium:** spleen
- **Right lumbar region:** right kidney and ascending colon
- **Umbilical region:** small intestine
- **Left lumbar region:** left kidney and descending colon
- **Right iliac fossa:** appendix, cecum, right ovary
- **Hypogastric region:** urinary bladder and pregnant uterus
- **Left iliac fossa :** sigmoid colon and left ovary

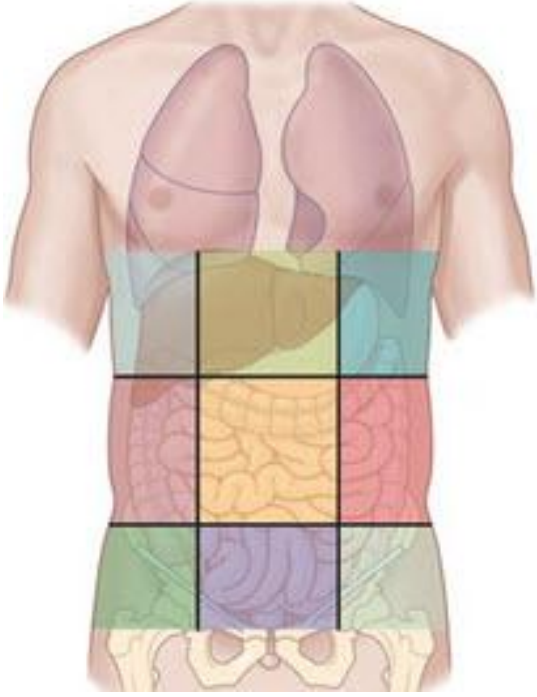

Right Hypochondriac Region • Liver • Gallbladder • Right kidney	**Epigastric Region** • Stomach • Liver • Pancreas • Right and left kidneys	**Left Hypochondriac Region** • Stomach • Liver (tip) • Left kidney • Spleen
Right Lumbar Region • Liver (tip) • Small intestines • Ascending colon • Right kidney	**Umbilical Region** • Stomach • Pancreas • Small intestines • Transverse colon	**Left Lumbar Region** • Small intestines • Descending colon • Left kidney
Right Iliac Region • Small intestines • Appendix • Cecum and ascending colon	**Hypogastric Region** • Small intestines • Sigmoid colon • Bladder	**Left Iliac Region** • Small intestines • Descending colon • Sigmoid colon

BY : Haif AlQahtani & Jenan almahfoudh

Peritoneum: serous membrane
Two layers > visceral peritoneum and parietal peritoneum
And serous fluid between them > <u>lubrication for internal organs movement</u>

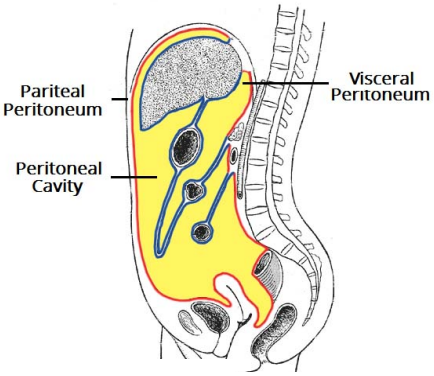

Peritoneum reflections:

- **Omentum**: lesser omentum connects the lesser curvature of the stomach to the liver and keeps it in place and greater omentum attached to the greater curvature to protect the abdominal structure and covers the intestine and storage site for fats.

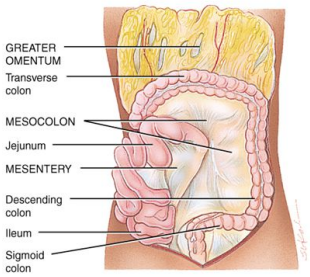

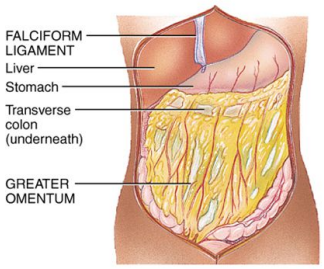

- **Mesenteries:** connects abdominal structures to the posterior wall of the abdomen. To keep them in position. BV run through it provides blood supply to the abdominal structures.

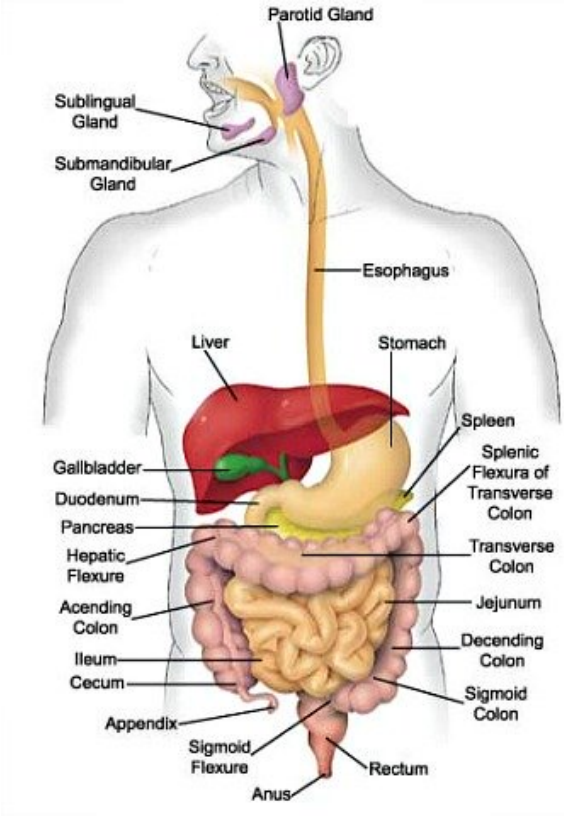

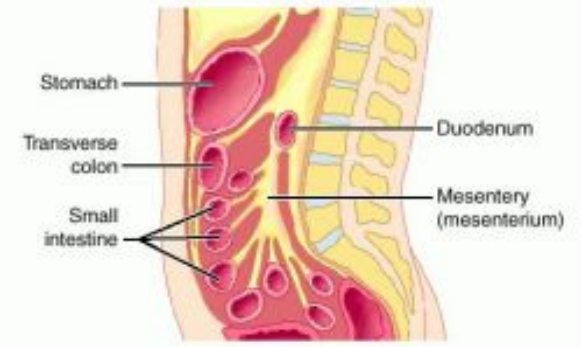

BY : Haif AlQahtani & Jenan almahfoudh

Abdomen Contents :

Digestive system:

- **Stomach** : J-shaped sack > main function digestion.

Upper part: fundus

Join esophagus and stomach: Cardia

Body > two curvatures (greater and lesser)

Last part: pylorus > has two parts > pyloric canal and pyloric sphincter

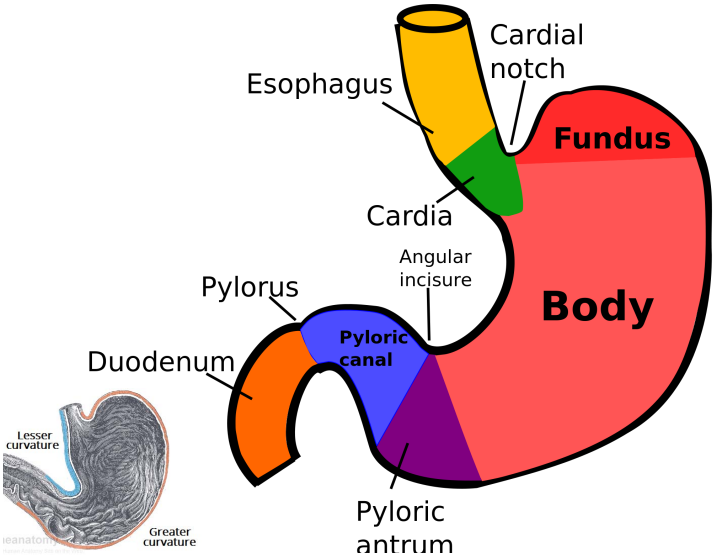

Inside the stomach there are folding's called **Rugea** : to increase the surface area

- **Small intestine:** called small because small diameter but long 6 m. Completes digestion of the stomach and main site of absorption of nutrients. three parts

Duodenum (1st part) C-shaped , Jejunum, and Ileum

Structures outside the peritoneal cavity is called **retroperitoneal structure** > ex. Duodenum

Sphincter lies between the stomach and duodenum

1st: **superior**, 2nd **descending** (opening for two ducts: liver and gall bladder is called common bile duct; digestion of fat and main pancreatic duct) the area where the ducts open is called Ampulla of vater, 3rd **transverse**, and 4thc**ascending parts**

- The head of the pancreas is close to the curvature of the duodenum.

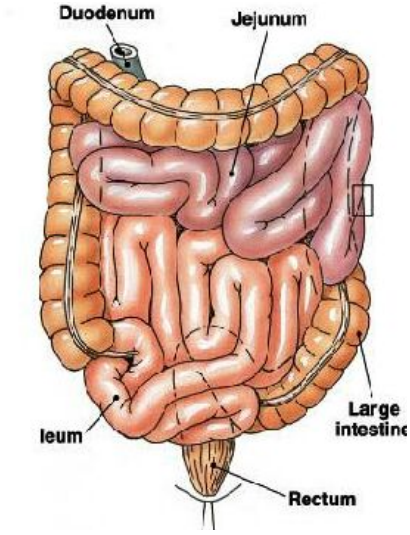

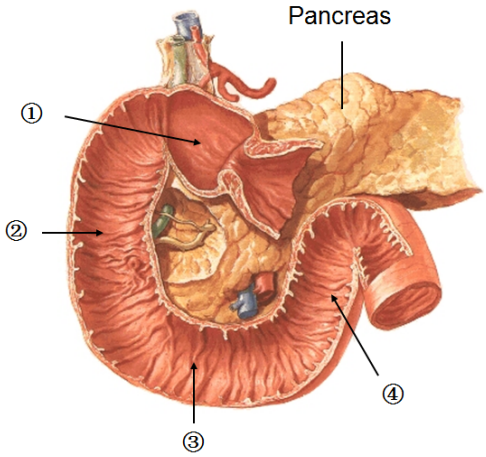

BY : Haif AlQahtani & Jenan almahfoudh

- **Large intestine**: large diameter, shorter than the small intestine 1.5 m. absorption of water and storage of waste materials.

  Folding's on the large intestine called Haustration. There's a line in the middle > smooth muscles on the outer surface called Taenia Coli.

  Parts of the large intestine:

  Cecum located in region #7 iliac fossa, ilium joins the cecum and forms a valve structure called **ileocecal valve** > insures one directional movement from the small intestine to the large. Attached to the cecum called the **appendix** and it has rich lymphatic tissue that's why it's more likely to be inflamed

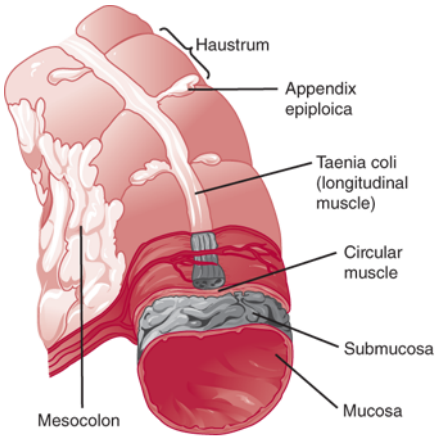

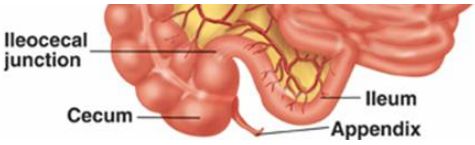

Colon: ascending colon, transverse, descending and sigmoid, and Rectum: ends at the anus. Anus has internal anal sphincter (formed by smooth muscles, parasympathetic, involuntary), anal canal and external anal sphincter (skeletal muscles, somatic, voluntary).

Rectum has receptors in its wall > stretch receptors > when it's full it'll stretch and send signals to the CNS that will stimulate the parasympathetic nervous system > opens the internal sphincter and the external is voluntary

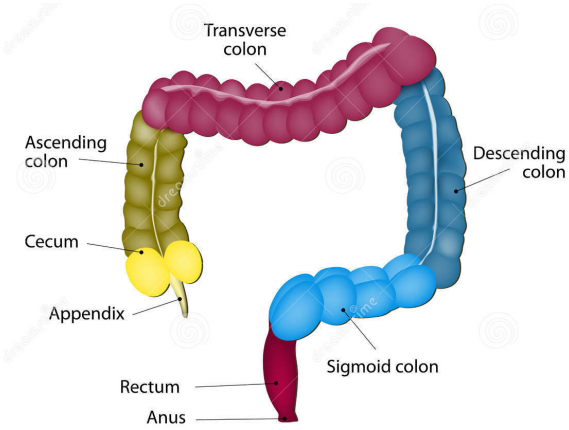

- **Liver**: largest gland in the body > located in the right hypochondriac > lies below the diaphragm on the right side. Three surfaces: anterior (right and left lobe by a ligament called **Falciform ligament**) from each lobe we'll get a duct > right hepatic duct and left hepatic duct > join together to form common hepatic duct, diaphragmatic surface (covered by the diaphragm), and visceral surface: porta hepatis > where structures leave the liver (arteries, veins, hepatic duct) 4 lobes.

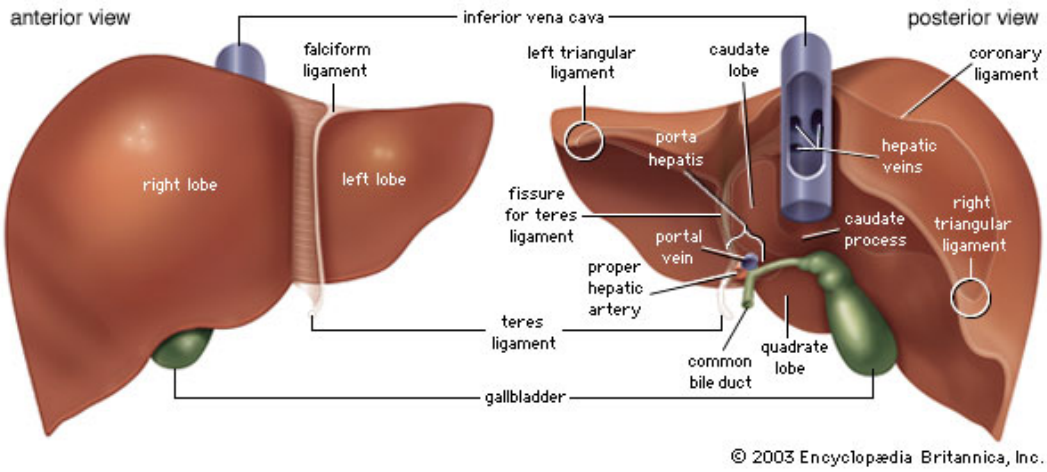

BY : Haif AlQahtani & Jenan almahfoudh

- **Gallbladder:** storage of bile > neck, body, fundus, and a cystic duct > joins the common hepatic duct to form common bile duct.

  Its primary **function** is to store and concentrate bile, a yellow-brown digestive enzyme produced by the liver.

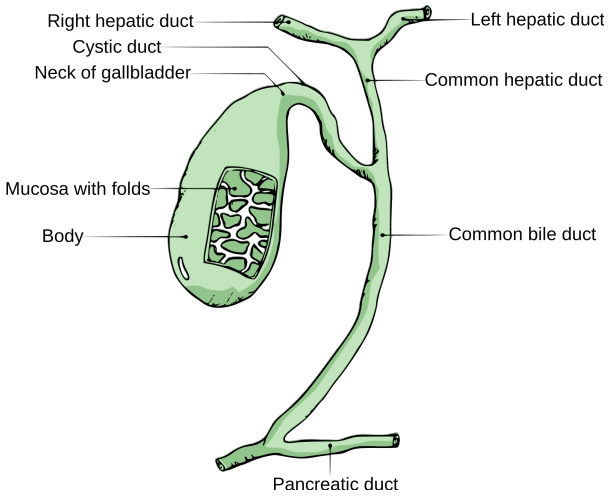

BY : Haif AlQahtani & Jenan almahfoudh