

THE ANATOMY OF MANDIBULAR ANTERIOR TEETH



DENTISCOPE



COLOR CODING

Cusp

Ridge

Fossa

Groove

Pit

Root



MANDIBULAR ANTERIOR


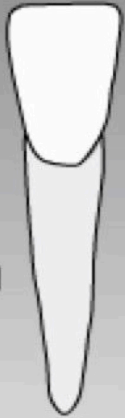
	Central Incisors	Lateral Incisors	Canines
Contact Areas	I 3 rd / I 3 rd	I 3 rd / I 3 rd more cervical	I 3 rd / M 3 rd
Cingulum	Centered	Distally inclined	Distally inclined less prominent than 13
Pulp Chamber: L/BL & MD Sections	Wide @cervical, tapers to apex	Larger than 41	Prominent pulp horn
Pulp Chamber: Cervical Cross Section	Oval	Oval larger than 41	Oval / Rectangular / Triangular
Buccal	Smooth, more convex at M 3 rd and symmetrical	-Smooth surface -Fan shaped	-Shallow depressions M/D of LR, concavity found D to LR @ C 3 rd -Labial Ridge -Mesial Incisal Slope is shorter than Distal
Lingual	-Smooth -Slight convexity -Palatal Fossa -Mesial and Distal Marginal Ridges -Incisal Ridge	-Palatal Fossa -Mesial and Distal Marginal Ridges -Incisal Ridge	-Mesial and Distal Marginal Ridges -Palatal Ridge -Mesial and Distal Palatal Fossas -Incisal Ridges and tips
Distal / Mesial	Convex	-	-Mesially, the mesial incisal ridge is visible
Root	1 root	1 root	1 root, longer
Incisally	Widest Labiolingually and can be symmetrical	Widest Labiolingually Incisal edge is inclined	Widest Labiolingually



Permanent Mandibular Right Central Incisor (41)



MANDIBULAR
ANTERIOR

Labial view **Lingual view**






Symmetrical - mesioincisal and distoincisal angles almost 90°

Distal Mesial Distal

Incisal view



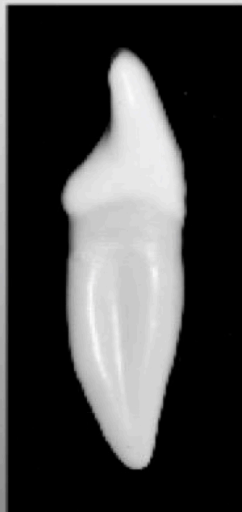




Incisal edge at right angles to line bisecting crown labiolingually

Labial Lingual Labial

Wider labiolingually than mesiodistally

Mesial view **Distal view**

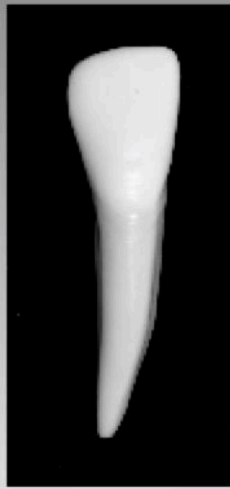

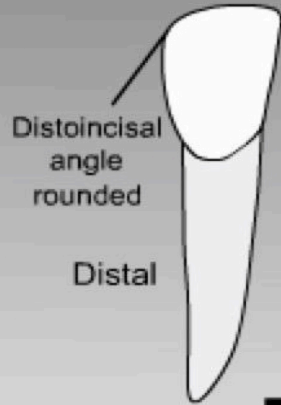
Permanent Mandibular Right Lateral Incisor (42)

ANTERIOR

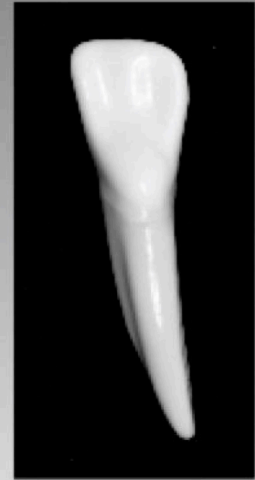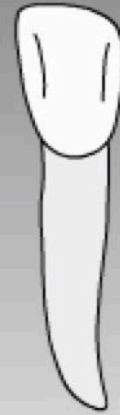MANDIBULAR



Labial view




Lingual view



Fan shaped

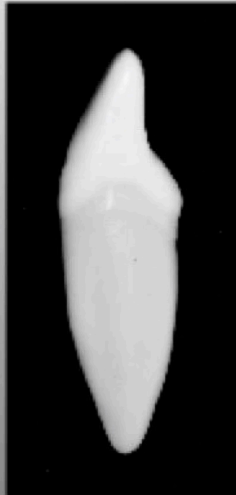
Slightly larger than central

Mesial

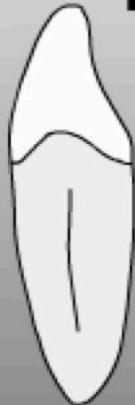

Distal portion of incisal edge twists to the lingual

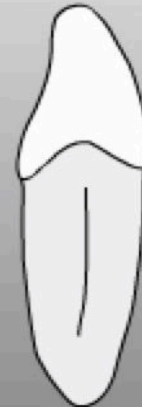Incisal view



Labial



Lingual

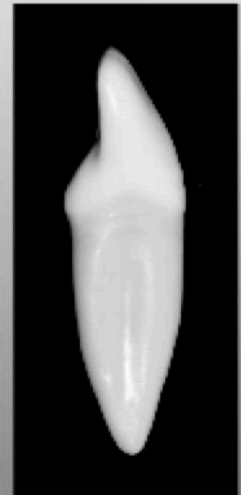


Labial

Wider labiolingually than mesiodistally

Mesial view

Distal view

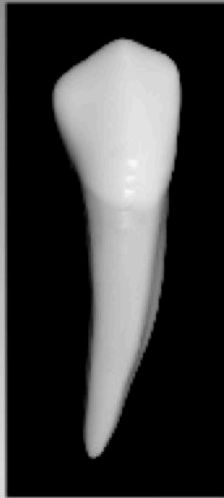



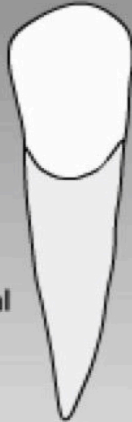Permanent Mandibular Right Canine (43)

ANTERIOR

MANDIBULAR



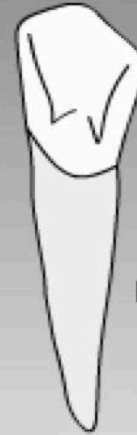Labial view



Distal

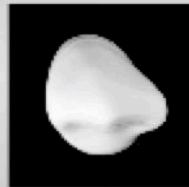
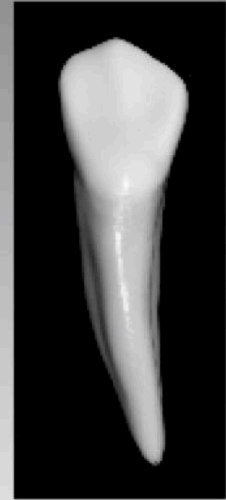Mesial surface of crown flattened

Lingual view



Distal

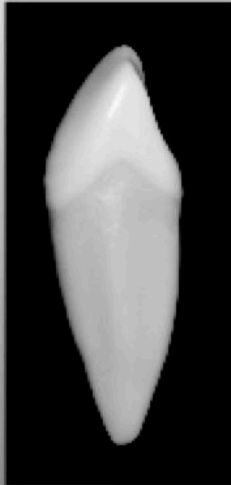Less distinct cingulum and marginal ridges



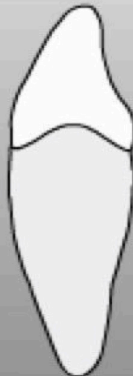Incisal view



Mesial

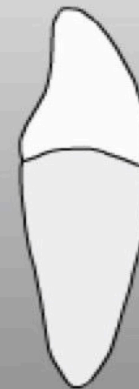

Labial



Mesial view

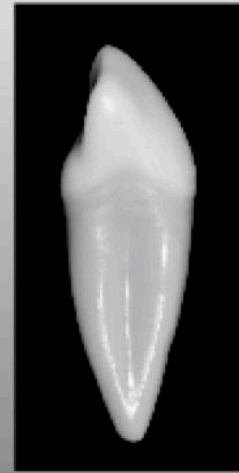Lingual



Cusp tilts lingually

Labial

Distal view





DENTISCOPE.ORG



ASK@DENTISCOPE.ORG



DENTISCOPE



DENTISCOPE