Enamel structure and function

Enamel :

1. tissue that is unique to teeth .
2. Covers the dentine of the crown (coronal dentin)
3. Thickest over cusps and incisal edges 2.5 mm
4. Gradually tapering to it's thinnest at the cervical margin of the crown (0.2 -0.5 mm)
5. Enamel's color is translucent since it's made of crystals

When you want to see enamel you usually do a ground section . (to preserve the minerals)

Radicular dentin is covered by cementum

A. The differing color of teeth <u>(why some people have greyish or yellowish colored teeth)</u> is an effect of dentin NOT ENAMEL. (enamel is translucent)
B. Thickness of enamel (thick enamel will not show the underlying dentin , but thin enamel will easily show the underlying dentin)

- Clinical crown = what you see in the oral cavity
- Anatomical crown = the part of the tooth

Properties of enamel :

1- Avascular
2- Acellular
3- Cannot be replaced if damaged (noble)
4- Not able to repair
5- Non vital
6- Dynamic
7- Exchanges ions with the surrounding environment
8- Enamel composition changes over lifetime
9- Demineralization ←→ remineralization
(normal balance but excessive dem. In erosion or caries)

- Rem. Products like fluoride and calcium phosphate are used in the prevention and management of caries and erosion.

Enamel is a noble tissue why ? because it cannot be replaced ,since it is acellular and avascular .

Enamel is considered to be dynamic but non vital ? since it undergoes cycles of remineralization and demineralization (affected by the environment) – this happens at microscopic level

Physical properties :

Hardness →

1- Hardest tissue in the body (due to:
   A. the amount of minerals , mature enamel has **96 % minerals** in the form of **hydroxy apatite crystals**)
   B. the crystal is thicker and longer
   C. the way the crystals are packed (rods and interrods)
2- Highly mineralized
3- Harder than dentine and bone
4- Highly resistance to abrasion

NOTE = bone , cementum and dentine also contain hexagonal (6 sided) hydroxy apatite crystals

The crystals will become shorter and thinner as you go towards inside →

Porosity →semipermeable (water and some small molecules and ions can cross)

Due to the presence of 3% water that is

- trapped within the crystals
- in between crystals

Hardness and porosity vary from one area of enamel to the other :

- harder and less porous at the external surface . (due to the presence of minerals)
- cuspal enamel harder and more dense than cervical enamel.

Enamel is brittle (fracture) :

- Low shear strength - poor at withstanding shear forces
- no flexibility due to the absence of collagen
- It is also considered to be brittle since it has a lot of minerals

low thermal conductivity an thermal expansion :protects the dental pulp from insults due to heat .

Translucent : due to the high crystal content

- The yellow hue (increases with age)→ relates to the underlying dentin
- Color varies between indvs

chemical composition of enamel :

	By tissue weight (how much minerals in their weight)
Mineral	**95-97%**
Organic material	**< or = 1%**
Water	**2-3%**

The nature of enamel :

Higher portion of mineral / inorganic components than dentine and bone

Calcium hydroxyapatite

- Large and very long hexagonal crystals - Ca10(po4)6(OH)2
- Highly organized molecular form rod shape
  Organized into rods (prisms) and interred enamel -(Prism is only used in UK)
- Rod and interred enamel exhibit different crystal orientation

Organic component of enamel :

- Exists as a fine network around the crystals and as thin layers around the rods
- Heterogeneous and many proteins
- But NO COLLAGEN (that's why it is brittle and inflexible)

Enamel Proteins :

important in :

play a role in morphogenesis -mediating the mineralization & formation of hydroxyl apatite crystals – without them there is no mineralization

1. Amelogenin
2. Enamilin
3. Ameloblastin
4. Tuftelin
5. Dentine sialoprotein
6. Enzymes
7. Serum proteins

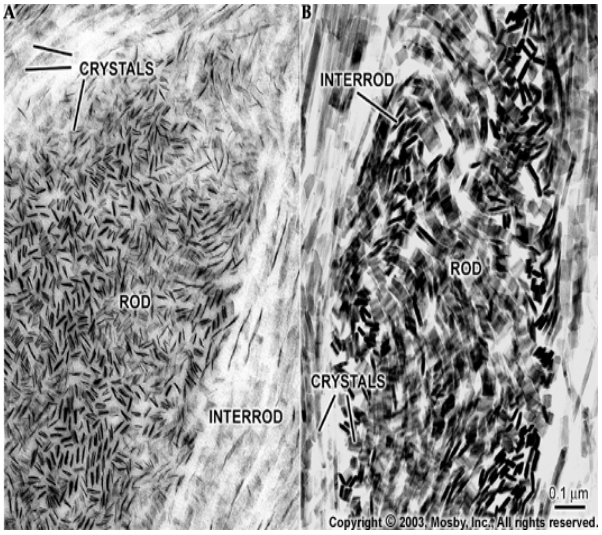

Clinical considerations :

1- stimulate reparative dentine
2- Periodontal regeneration

(still in research stage)

Most common protein in:

- immature enamel → amelogenin
- In mature enamel → enamilin

The amount of amelogenin at the beginning is high then it decreases with time .

Enamel mineralization :

- Ameleoblasts secrete enamel matrix proteins
- HA crystals precipitate immediately within this matrix
- Amelogenin provides ideal substrate for the precipitation of hydroxyapatite form.
  Environment supersaturated of calcium and phosphate
- **No matrix vesicles are associated with the mineralization of enamel (explanation below)**
- Enamel is secreted as partially calcified tissue (no-pre enamel) with 70% mineral .
- As crystal grows the amelgenin adjacent to it as part of enamilin goes into solution (enamel fluid)
- Mineralization will increase during maturation till 96 %

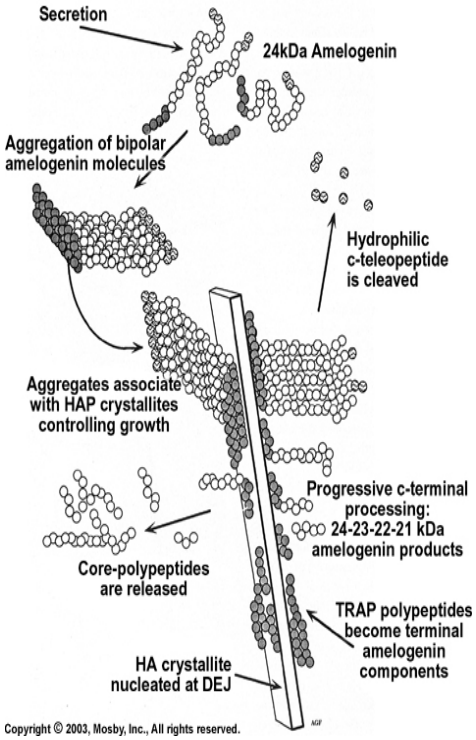

Proteins are always on the surface of the crystals and in order for the crystals to grow we need to remove the proteins away and give it space to grow . so with time the protein will get less and less

Immature enamel contains 70% inorganic and 30% organic with water so we go from 30% to 4% .

So the space that the proteins leave for the crystal to grow is 26%

Explanation of matrix vesicles :

Nucleation is the center for precipitation , for enamel the center is the crystals of the dentin while in dentin the center for precipitation is the matrix vesicles .

at the DEJ , dentin is mineralized first by the activation of odontoblasts and formation of **dentin matrix vesicles , the areas that will first be mineralized .**

And since HA crystals and nucleation are already formed in the dentin so the enamel will continue formation from the DEJ and **there are no matrix vesicles in enamel formation .**

Dentin and enamel have different ways for mineralization but both contain HA crystals ,

Enamel is first secreted as immature enamel which has (70% inorganic and 30 % organic) organic = proteins and water . this amount at the end of maturation phase will become 4 % (enamelin and water) amelogenin will degrade slowly (it will stay in the enamel fluid)

In dentine we have pre dentin (which is not mineralized) but in enamel you secrete partially mineralized enamel (no pre enamel)

During enamel formation maturation phase is the longest (the crystals will grow bigger and the spaces in between them decreases)

Structure of Enamel :

The basic organization unite in enamel is : Enamel rods (prisms)- tighly packed = individual E.rods extends from the dentine out to the enamel .

Exceptions : (where we don't have rods – Rodless enamel or initial enamel)

- Immediately adjacent to the dentine where there is a very thin zone of rodless enamel
- And for the outermost 30- 50 um of enamel .

Q:Why do we have 2 areas with rods and 2 areas without rods ?

A: Ameleoblasts will develop toms process only for a certain period of time when those processes withdraw they leave those areas .

Shape of Enamel rod :

- **In cross section → rods have a keyhole shape with the rods arranged in horizontal rows.**
- **In longitudinal section → rods show a wavy or a sinusodial form**



Q:What makes the rods tightly packed ?

A:The rod shape and their arrangement although they are not straight and they show different degrees of curvature .

Interrod : the region surrounding each rod , consists of crystals arranged in a different way than the rod crystals .

- **What causes the rod and interrod shape ? the different orientation of enamel crystals .**
- **How can you distinguish between rods and interrods ? the only difference is the crystal orientation .**
- **Enamel crystals in the head of the enamel rod are oriented parallel to the long axis of the rod, while in the tail they are diverged slightly (65 degrees) from the long axis .**
- **In permanent teeth the E.rods near the CEJ tilt slightly towards the root .**

Clinical importance : understanding the enamel orientation is very important in restorative dentistry , because undermined enamel (enamel not supported by dentin) is prone to fracture

Each E.rod contains several million crystals

The enamel rods differ in length according to there orientation which follows the thickness of the enamel .

Arrangement of enamel rods within a tooth crown is complex and appears to be based on a spiral shape .

Generally the orientation of the rod is 90 degree (perpendicular) to the enamel surface .

The arrangement of the rods influence the properties of enamel (hardness) .

Rod Sheath :

Organic matrix exist between crystals (in the rod) but most exist at the margins of the enamel rod making the rod sheath .

The protein in the rod sheath is Ameloblastin . (but it is suggested that more than ne protein exists)

- The protein between crystals →amelogenin and enamilin
- The protein surrounding the rod → ameloblastin

Enamel Rod Arrangement :

Gnarled enamel : enamel rods are twisted on each other or bent at different axis than adjacent group .

In the cuspal / incisal regions of teeth the rods are arranged in a spiral way. This arrangement provides great strength to the enamel in that area (crushing or bitting surfaces) . so enamel in this area is referred to gnarled enamel .

Microscopic features of mature enamel :

1 – enamel lamellae:

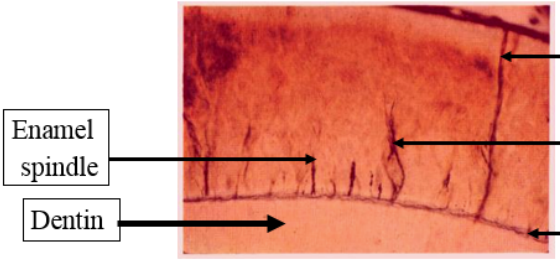

- Seen with LM in ground cross sections as a crack on the surface of the enamel that may develop during enamel formation or during tooth function .
- Extend inwards from the surface of the enamel .
- Represent defects in the enamel with abnormally high levels of organic material , this defect may be considered as weakness in tooth and may form a road of entry of bacteria that initiate caries .

How can you differentiate between lamellae and a crack ? lamellae has high amounts of proteins in it .

2- Enamel tufts :

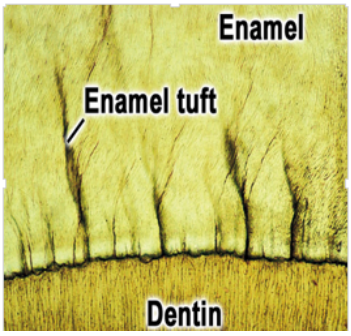

Seen with LM in ground cross sections

Extend outward from Dej into 1/5th or 1/10th of enamel thickness .

Dark short lines that are branched and they represent :

Areas where rod orientation changes

Higher levels of protein than surrounding enamel (when the rods change their orientation , the space created will be filled with proteins)

3- Enamel spindles :

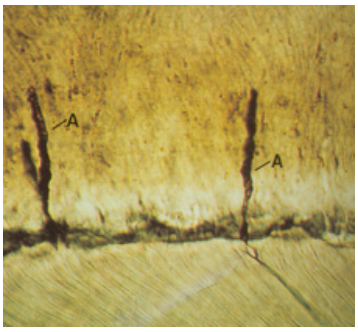

Seen in LM in ground cross sections

short dark finger extensions from DEJ into enamel

occaisionally the odontoblast processes pass across the basement membrane before it is mineralized into the DEJ

some of these processes get trapped in the mineralized enamel and termed enamel spindle .

this is why caries spread faster in dentine than enamel because the E.spindle contain organic material.

4- Striae of retzius :

Seen in LM in mineralized ground sections of enamel .

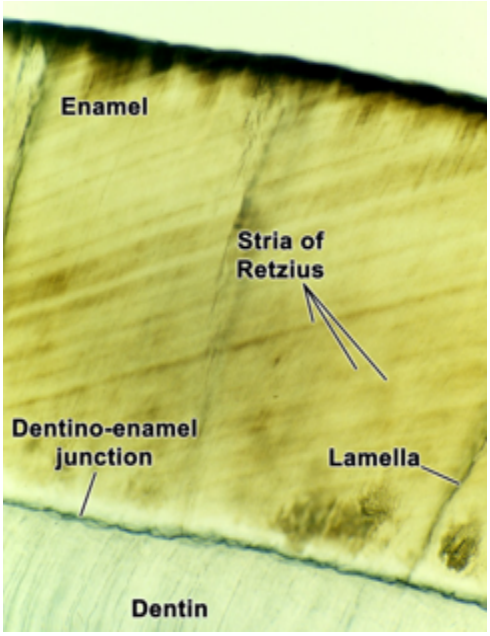

Longituidinal tooth sections – striae of retzuis are seen as dark striations / series f dark lines running from the DEJ to enamel surface in cuspal direction (surrounding the tip of dentine)

➔ **Why do these lines appear ?**

- **Not clear** (might be due to the difference between day and night , since cells work mostly at night (secret) and rest during the day . this is logical because a lot of primary teeth don't have striae of retzius . (primary teeth develop in intrauterus , so the baby can't sense the difference between day and night)
- **Related to the incremental deposition of enamel weekly**
- **Recruitment of newly differentiated secretory ameloblasts** (when ameloblasts secrete then start

maturation phase a different ameloblasts will start their secretion but in a different manner or way which causes those oblique lines)

These lines are **more prominent in permanent teeth** and they reflect→ variations in structure and mineralization that occurs during enamel growth .

These structural differences is either due to normal physiological changes of the ameloblasts or as a result of functional interruption such as neonatal lines.

Neonatal line:



Darkened line that is not always present

Represents the border line between the enamel matrix formed before and after birth (between pre natal and post natal enamel)

May be formed due to a sudden change in the environment (delivery of the baby) after birth which leads to metabolic disturbance of the ameleoblasts

Which teeth will have neonatal lines ?

Permenant Molars , in the 3rd molar we don't have neonatal lines since it forms all after birth .

Hunter schreger bands :

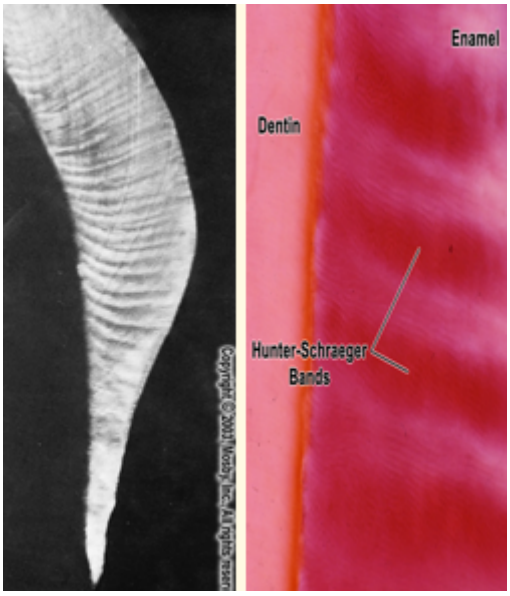

Group of rods with different rod orientation

- Optical phenomena seen by refected light as a pattern of banding
- Appears as dark and light alternating zones that can be reversed by changing the direction of light
- Seen in longitudinal sections of enamel in the **inner 2/3 of enamel .**

Surface enamel :

Chemistry and physical characteristics differ from those of subsurface enamel .

(less soluble / harder / less porous)

Features of surface enamel :

1. Straie of retzius
2. Perikymata
3. Aprismatic enamel

Perikymata :

- Concentric linear grooves where straie of retzius reach the enamel surface.

(impressions that are seen only at newly erupted teeth or at the cervical region where there are no mastication pressure , in our teeth with mastication those lines disappear)

- Parallel to CEJ
- Separated by ridges
- Present where enamel not abraded or eroded (cervical areas)

Aprismatic enamel :

- Most superficial enamel
- Present in teeth that are not abraded or eroded
- Highly mineralized (caries resistant and acid etch must extend through)
- Has perikymata

Age Changes :

1. Enamel permeability becomes less with age due to increase in the crystal size and reduce in spaces .
2. Enamel that is worn away in regions of masticatory attrition causes sensitive teeth (due to exposure of underlying dentin)
3. Enamel becomes harder and darker in color
4. Reduction in caries incidence since enamel becomes more mineralize and less permeability to water and bacteria .
5. The composition of the surface layer changes due to ionic exchange with the environment .

Acid etching :

Used in :

1. fissure sealants
2. bonding of restorations to enamel
3. cementing ortho brackets

to increase **surface roughness and increasing surface area** to inc the bonding between the material and the enamel .

- acid etching removes plaque with thin layer of enamel .
- it increases the porosity of the surface for better bonding of the restoration .

- it depends on location of the area being etched and the direction of enamel rods (you will get different patterns of acid etching)

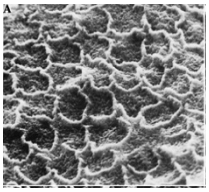

here acid etching removed the rods.

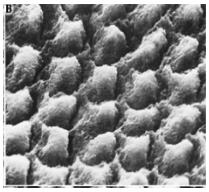

removed interrods

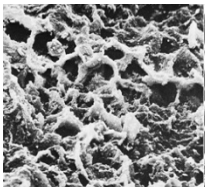

removed rods + interrod

rods + interrrods

(diferrent areas)